

Central Venous Catheter

Insertion Guide

written and illustrated by
Philippe Le Fevre

About This Guide

Central venous catheters (CVCs) are useful devices essential to the care of critically ill patients. However, CVCs are associated with life threatening complications. To minimise these complications each CVC insertion needs to be carefully planned with regard to indication, type, site, insertion procedure and subsequent management.

Date of last edit: November 2017
Correspondence via www.philippelefevre.com

Making the most of the available evidence this guide hopes to teach you:

- When and when not to insert a central line
- To choose the right insertion site for the patient in front of you
- To insert a central line as safely as possible

The ongoing care and maintenance of central lines is not covered by this guide.

This written guide is accompanied by a companion instructional video and series of online MCQ questions.

Contents

Part 1: Theory

What is a Central Venous Catheter?	2
Types of Central Venous Catheter	2
Complications	2
Experience and Seeking Help	2
Choosing the Most Appropriate Site	3
Staying Clean	5
Electrical Safety	5
Ultrasound Guidance	6
Ideal Tip Position	8
Depth Guide	9
Detecting Arterial Puncture	9

Part 2: Procedure

The Seldinger Technique	10
Internal Jugular Vein	14
Subclavian and Axillary Veins	15
Femoral Vein	16
Peripherally Inserted Central Catheter (PICC)	17
Securing and Dressing the Line	19

Part 1: Theory

What is a Central Venous Catheter?

A central venous catheter, often called a central line, is an intravascular catheter placed so that the tip lies near the centre of circulation in one of the venae cavae. These veins have a large luminal diameter and high blood flow that makes them suitable for:

- Administration of sclerosing infusions
- High flow blood access for dialysis or plasmapheresis
- Haemodynamic monitoring
- Venous access when peripheral access is unavailable
- Long term venous access

Types of Central Venous Catheter

Broadly speaking, there are two types of central line: short centrally inserted central catheters (CICCs) inserted into the axillary, subclavian, internal jugular or femoral veins; and longer peripherally inserted central catheters (PICCs) usually inserted into one of the mid arm veins.

Central lines can also be categorised by:

- Site of insertion
- Tunnelling
- Antibacterial coating
- Length
- Number of lumens
- Total and luminal gauge

Complications

The more common or serious complications of a central line insertion include:

- Pneumothorax
- Air embolus
- Haematoma
- Haemorrhage
- Thrombosis
- Stenosis
- Arterial puncture / catheterisation
- Incorrect catheter tip position
- Central vein perforation
- Tamponade
- Cardiac arrhythmia
- Embolised, fractured or irretrievable guide wires
- Infection

Experience and Seeking Help

As with most medical procedures, experienced operators have fewer complications. Central venous access by someone who has performed more than 50 catheterisations is half as likely to result in a mechanical complication as someone who has performed less than 50.¹ High risk catheterisations should be recognised as such and performed by experienced staff.

The incidence of mechanical complications after three or more failed insertion attempts is six times the rate after one attempt.² If you are having trouble, seek help.

Choosing the Most Appropriate Site

Choosing the most appropriate site will vary: Patients with coagulopathy, active injuries, old scars, skeletal abnormalities, vascular surgery, venous thrombosis, stenosis, presence of vascular filters, pacemakers and defibrillators, and a history of difficult central venous access should inform your decision making process. It is important to review each patient's history, perform a focussed vascular examination, examine the available relevant radiological images and investigate for coagulopathy.

PATIENT ASSESSMENT

History

- Respiratory failure
- Ability to lie flat
- Claustrophobia
- Clotting disorders
- Allergies (esp. chlorhexidine)
- Previous venous access devices
- Pacemaker / ICD / IVC filter
- Likely need for long term dialysis

Examination

- Scars (surgical and vascular procedures)
- Pacemaker / ICD
- Confusion & level of cooperation
- Skin infection / inflammation

Investigations

- Clotting studies
- Platelet count
- Ultrasound
- Chest X Ray to predict depth

PERIPHERALLY INSERTED CENTRAL CATHETERS

Practical Application

Being true central catheters, PICCs are appropriate for the slow administration of sclerosing solutions like TPN. PICCs have two important practical shortcomings. The first is that their long length and small diameter limits their flow rate and makes them inappropriate for rapid fluid resuscitation. The second limitation is that PICCs often don't provide enough lumens for critically ill patients who need multiple concurrent incompatible infusions. Three and four lumen PICCs are commercially available but are associated with an increased risk of thrombosis.³

Safety

Over the last 20 years, PICCs have become more widely used, mainly due to their low risk of early serious complications such as pleural injury and bleeding. They are no safer than CICCs when longer term considerations are considered.^{4,5}

Misplacement

A systematic review of five satisfactory studies reflecting 432 PICCs and 641 CICCs found that radiographic misplacement occurred more often after PICC placement (9.3% vs 3.4%; odds ratio 3.76, 95% CI 1.75–8.07).⁵

Thrombosis

When screened for in critically unwell patients the incidence of PICC associated DVT is high (23%).⁶ Systematic review of 7 non-randomised studies found that thrombophlebitis was reported dramatically more often with PICCs than CICCs (7.8 vs 0.75 per 1000 catheter-days; odds ratio 5.82, 95% CI 2.37–14.2).⁵ A few patients with DVT suffer severe thromboembolic complications, but in most cases the sequelae of catheter associated DVT are not clear.³ There is a well established correlation between thrombosis and catheter related sepsis^{2,7} but it is not known whether thrombosis predisposes for sepsis or vice versa.

PICC

Advantages

- Low rate of infection
- Very low risk of pleural injury

Disadvantages

- Low maximal flow rate
- Limited number of lumens
- High rate of thrombus formation
- High rate of misplacement

Infection

Experience of PICC use in low acuity patients has formed the impression amongst clinicians that PICCs carry a lower risk of infection than CICCs. However, formal comparison in randomised controlled trials of the rate of catheter related bloodstream infections (CR-BSI) in critically ill patients shows no difference between PICCs and CICCs.^{8,9}

AXILLARY & SUBCLAVIAN VEINS

Subclavian central lines carry the lowest risk of arterial puncture and line sepsis. A methodologically sound RCT compared subclavian with femoral central line insertions. It found subclavian access to be associated with a significantly lower rate of any infectious complications (4.5% vs 19.8%; $P > 0.001$) and a trend toward a lower rate of suspected or confirmed catheter related bloodstream infections (1.5% vs 4.4%; $P = 0.07$).¹⁰

The more recent 3SITES trial is well conducted large RCT comparing Internal Jugular, Femoral and Subclavian vein sites for CVC insertion. This study confirmed the findings of smaller prior studies¹⁰ that the subclavian site is associated with the lowest rate of blood stream infections (subclavian 1.5, internal jugular 3.6, and femoral 4.6 per 1000 catheter-days; $P = 0.02$).¹¹

The major risk of subclavian vein catheterisation is pleural injury leading to pneumothorax or haemothorax — serious complications that often require a chest drain insertion. The 3SITES found similar rates of pneumothorax as in trials done previously (subclavian 1.5%, internal jugular 0.5%).¹¹ Of note, in the 3SITES study ultrasound was only used in 15% of subclavian CVC insertions. Ultrasound guidance may reduce the incidence of pneumothorax making this less of a reason to avoid the subclavian site but the evidence is lacking.

Patients who are in severe respiratory failure may not have the reserves to contend with a pneumothorax and so the subclavian site should be avoided. If a patient has a chest drain in situ consider inserting a subclavian or axillary line on the same side. Blood loss into a haemothorax can be catastrophic. A subclavian or axillary line should not be inserted in any significantly coagulopathic patient ($INR > 1.5$ or platelets $< 50\ 000/\mu\text{L}$). The internal jugular and basilic veins are compressible with external pressure and much more appropriate sites for central access in a patient who is prone to bleed.

Catheterisation of the subclavian vein carries a high risk of stenosis, especially when catheterised with a haemodialysis catheter. The subclavian vein should be avoided for haemodialysis if possible, not just because of the increased risk of stenosis but because subclavian stenosis will complicate subsequent haemodialysis access.^{12,13}

Subclavian lines are the most comfortable of centrally inserted central catheters.¹⁴ This and their low incidence of infection makes them suitable for long term and outpatient use.

Subclavian central catheters should not be inserted on the same side as a preexisting cardiac pacemaker, where there is risk of dislodging trans venous pacing wires.

AXILLARY & SUBCLAVIAN

Advantages

- Lowest rates of infection (1.5 per 1000 catheter days)
- Lowest rates of thrombosis
- Comfortable
- Good flow rates for dialysis

Disadvantages

- Non compressible site and not suitable with bleeding tendency
- Higher rate of stenosis with implications for long term dialysis
- Highest rate of pneumothorax (1.5%)

FEMORAL VEIN

Femoral vein central lines carry the highest risk of bacterial line colonisation and catheter related blood stream infections.^{10,11} In addition, the insertion of a central line into the femoral vein carries the highest rate of arterial puncture, haematoma and haemorrhage.¹⁰ The femoral vein is compressible makes it preferable to the subclavian and axillary veins in coagulopathic patients. However, it is better still to use the internal jugular vein in these patients. Blood loss from femoral haemorrhage can be massive and concealed into the retroperitoneal space. Femoral vein catheters also cause the highest rate of symptomatic thrombosis (femoral 1.4%, internal jugular 0.9%, subclavian 0.5%). Femoral catheterisation has the advantage that it carries a very low risk of pleural injury and air embolism.

Femoral catheters make hip flexion awkward and cause an impediment to patient mobilisation and physiotherapy.

Obtaining central venous access during a resuscitation can help the delivery of drugs to the heart and is occasionally the only viable venous access (interosseous aside). In a small, randomised controlled study of patients receiving CPR, directly ultrasound-guided femoral catheterisation was faster and more likely to be successful than alternative approaches.¹⁵ Catheterising the internal jugular or subclavian veins during CPR will tend to interfere with chest compressions and airway management. It is worth remembering that during chest compressions the femoral vein will be pulsatile. Extra care should be taken to prevent needle stick injuries in the crowded resuscitation environment.

In a patient who has an inferior vena cava filter, femoral line placement should only be performed by a radiologist with the benefit of fluoroscopy to ensure that the guide wire does not become entangled with the filter.¹⁶

FEMORAL

Advantages

- Compressible site
- No risk of pleural injury
- Good flow rates for dialysis
- Most accessible site during CPR

Disadvantages

- Highest rate of infection (4.6 per 1000 catheter days)
- Lowest rate of success
- Highest rate of inadvertent arterial cannulation
- Impedes patient mobility
- Unsuitable for measuring superior vena cava pressures
- Caution in patients with an inferior vena caval filter

INTERNAL JUGULAR VEIN

Internal jugular catheter insertion carries a higher risk of line sepsis and arterial puncture than the subclavian site but a lower risk of pneumothorax and haemothorax.

Of the three CICC sites the internal jugular vein is the most suitable for coagulopathic patients. An internal jugular catheter is incompatible with a rigid cervical spine collar.

As an aside, one of the more remarkable complications listed in the supplementary material of the 3SITES study was of a patient that needed emergent reintubation following an endotracheal tube cuff perforation by the needle during an attempted internal jugular CVC insertion!¹¹

Given the low rate of immediate complications, the internal jugular vein is usually the most appropriate site for novice proceduralists to begin their CVC insertion practice.

INTERNAL JUGULAR

Advantages

- Moderate rate of infection — 3.6 per 1000 catheter days
- Low risk of pleural injury 0.5%

Disadvantages

- Potential to increase venous resistance and exacerbate cerebral oedema

LEFT vs. RIGHT

For a number of reasons, central lines of the upper body are better inserted on the right.

Left sided lines have to traverse the acute angle between the left innominate vein and superior vena cava. As a consequence catheters inserted via the left innominate are associated with a greater risk of delayed perforation^{17,18} thrombosis,¹⁹ and greater resistance to flow.

The internal jugular vein has a larger diameter (1.54 vs 1.08 cm; $P < .0001$) and runs more superficially (1.74 vs 1.87 cm; $P < .0001$) on the right than the left.²⁰

Most of the body's lymph drains via the thoracic duct into the proximal end of the left subclavian vein. Not surprisingly, and although rare, the risk of thoracic duct damage and chylothorax is higher with central access via the left internal jugular and subclavian veins.^{21,22}

The apical lobe of the lung reaches more superiorly on the left and implies a greater risk of pleural injury from central line insertions on the left.²³

One factor in favour of left sided insertions is that catheters advanced along the left subclavian vein (PICCs included) are a little less likely to inadvertently divert superiorly into the internal jugular vein.²⁴

A randomised controlled trial found catheterisation of the left internal jugular vein was more time consuming; it required more attempts; and it was associated with a greater number of complications when compared to the right side.²⁵

One last consideration is that right handed proceduralists will find central line insertions on the right of the patient more comfortable and easier to accomplish. Vice versa for left handed proceduralists.

Never attempt central lines on opposite sides of the chest without performing a chest X-ray in between to avoid bilateral pneumothoraces.²⁶

RIGHT VS LEFT

Advantages of the Right

- IJ has larger diameter
- IJ is more superficial
- Lower risk of delayed perforation
- Better flows for dialysis
- Lower risk of thoracic duct damage
- Lower risk of pleural injury

Advantages of the Left

- Catheters fed through the left subclavian vein are less likely to divert up the internal jugular vein

SUMMARY

Make yourself aware of each patient's specific considerations. In the non-coagulopathic patient who is not in severe respiratory failure, a subclavian central line is the most appropriate choice. That leaves the internal jugular vein as a useful site for patients with a coagulopathy or profound respiratory failure providing they can lie flat for the procedure. Femoral lines are useful as an alternative when there is a compelling reason to avoid an upper body central line, often because of venous thrombosis, stenosis or a preexisting central line already residing in the SVC. A peripherally inserted central catheter is an alternative unless the line is required for rapid infusions, thermolysis or multiple concurrent but incompatible infusions. In the upper body the right side of the patient is preferable to the left.

Staying Clean

Catheter associated sepsis is the most common, serious complication of central venous access. The incidence of catheter related blood stream infections (CR-BSI) is about 1 to 8 per 1000 catheter-days in general intensive care patients²⁷ and even higher, 15 per 1000 catheter-days, in burns patients. The rate is substantially lower in the outpatient population — approximately 0.5 per 1000 catheter days.²⁸

Barrier precautions make a difference. The use of a face mask, hair-cap, sterile gown, sterile gloves, and a large sterile drape dramatically reduces the rate of CR-BSIs when compared with sterile gloves and a small drape alone (relative risk 0.16; P = 0.06).²

The assistant should wear a face mask and hair-cap throughout the procedure.

Open a sterile gown and fenestrated drape pack onto a dedicated clean trolley. The blue water-repellent sheet that covers the gown and drape, when opened out, serves to cover the trolley and provide a sterile surface. Open the sterile line insertion equipment onto this surface with care to maintain sterility.

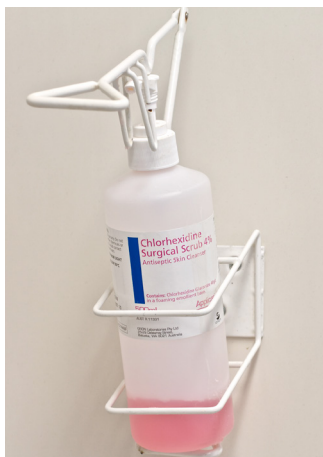

FIGURE 1 Hand Wash
Pink 4% chlorhexidine surgical scrub.

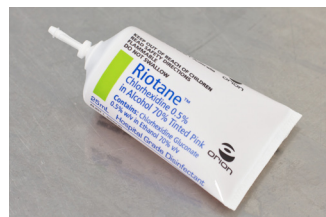

FIGURE 2 Skin Disinfectant
Pink chlorhexidine and alcohol solution.

PRECAUTIONS

- Sterile equipment setup
 - Gown, glove, mask and hair cap
 - Effective hand washing with 4% chlorhexidine surgical scrub
 - Patient skin antiseptics with chlorhexidine and alcohol solution
 - Sterile drape
 - Antimicrobially coated catheter
- Should sterile precautions be compromised, abandon the procedure and reattempt with full aseptic technique

The sterile equipment setup must be used immediately after opening to minimise airborne contamination. If for some reason there is a delay after opening the equipment a new set of sterile equipment should be prepared.

The proceduralist should hand wash with 4% chlorhexidine surgical scrub (*Figure 1*) for a minimum of 2 minutes. Guidelines for effective hand washing are available from Hand Hygiene Australia (www.hha.org.au).

Chlorhexidine and alcohol solution (*Figure 2*) should be used to disinfect the skin in preparation for the insertion. If the patient has an allergy to chlorhexidine a povidone-iodine solution can be used. Chlorhexidine-based solutions for skin preparation reduce the rate of catheter-related bloodstream infection by half when compared with povidone-iodine solutions (relative risk 0.51; CI, 0.27–0.97).²⁹ The reason for the difference probably relates to chlorhexidine's higher efficacy against gram positive bacteria. The most frequent causative organisms of line sepsis are coagulase-negative staphylococci, *Staphylococcus aureus*, enterococci, and *Candida* species. Gram negative species are rarely responsible.³⁰

Antiseptic precautions make a very big difference to patient outcomes. If these precautions are accidentally broken abandon and reattempt the procedure with full precautions.

Electrical Safety

Most patient treatment rooms are 'body-protected electrical areas'. This means that precautions have been taken to prevent accidental macroshocks (greater than 10 mA) (*Figure 3*). However, a small shock well below this threshold, transmitted directly to a patient's heart via a guide wire could easily trigger a fatal arrhythmia. For this reason any central line insertion should be conducted in a 'cardiac-protected electrical area' where precautions have been taken to prevent even microshocks (greater than 100 µA). Look for the appropriate electrical safety sign (*Figure 4*). In many hospitals this will require the patient to be in the ICU or theatres.



FIGURE 3 Body-Protected Sign
Area suitable for most patient treatments, but not CVC insertions.



FIGURE 4 Cardiac-Protected Sign
Area suitable for CVC insertion provided that the electrical safety test is within date — check the stamp.

Ultrasound Guidance

FUNDAMENTALS

Ultrasonic sound waves radiate out from an ultrasound probe, reflect at interfaces between substances and can be detected back in the probe. The time taken for a sound wave to be emitted, reflected and then detected indicates the depth of the reflection. The pattern of timed reflections along the length of the probe is compiled to produce a real-time 2-dimensional image of the medium beneath the probe. The degree to which sound is reflected at an interface is dependent on the difference in impedance between the two mediums. When travelling through a homogenous medium, for example blood inside a blood vessel, the sound waves are transmitted freely, there is no reflection and the medium appears dark. It is thanks to the subtle heterogeneity of soft tissues that they have definition on ultrasound. When there is a large change in acoustic impedance

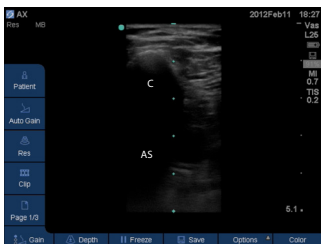


FIGURE 5 Acoustic Shadow
The clavicle casts an acoustic shadow that obscures underlying structures. C — clavicle, AS — acoustic shadow.

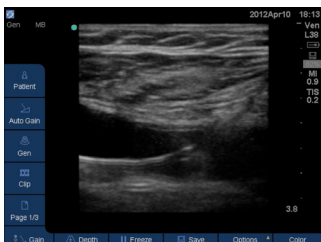

FIGURE 6 Ultrasound Reverberation
This long axis view shows a CVC guide wire entering into the femoral vein. Back and forth reflections between the guide wire and the deep vein wall have caused a reverberation artefact. Also, notice the difference in the appearance of the wire depending on its orientation to the ultrasound probe. It shows up as a clear echogenic line where it is 'in plane' with the probe.

at an interface, as between soft tissue and bone, almost all of the sound is reflected. This creates a high contrast impression of the interface and a shadow beneath it where ultrasound imaging is lost (Figure 5). Indeed, this is why gel is needed between the probe and skin — to displace highly reflective air-tissue interfaces. When there are two highly reflective surfaces in view, for example two ribs, sound can bounce between them creating reverberation artefact in the image (Figure 6). As the sound energy travels out away from the probe it is dissipated and absorbed. To correct for this natural decay in energy and image intensity, the ultrasound machine amplifies the image according to depth. This can give rise to acoustic enhancement of tissues below areas of low energy absorption (Figure 7).

A reflecting surface in motion with respect to the sound wave will affect the frequency of the reflected sound (the Doppler effect). This information is readily detected by the ultrasound probe and can be superimposed as a colour pattern on a duplex image (Figure 8). It is

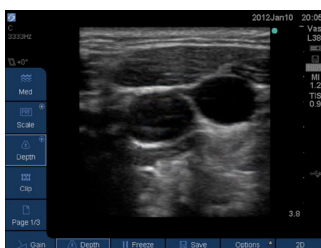

FIGURE 7 Acoustic Enhancement
In this short axis view of the carotid sheath the ultrasound signal from beneath the large fluid filled vessels has been enhanced.

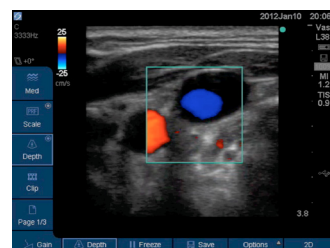


FIGURE 8 Duplex Ultrasound
This short axis duplex view of the carotid sheath shows venous blood flow away from the probe (blue) and arterial blood flow towards the probe (red).

EQUIPMENT

Some ultrasound machines are specifically designed for vascular access (Figure 9) almost any ultrasound machine can be adjusted to suit. It is best to use a linear probe with a high frequency range (> 5 MHz) to provide fine detail at a shallow depth.

In general there are just 4 settings that you will need to adjust:

1. On/off button
2. Gain — the degree of signal amplification
3. Depth — use the minimum depth required to visualise all important structures (this uses the highest frequency and gives the greatest resolution). There are centimetre and half-centimetre depth marks superimposed on the image.
4. Doppler (sometimes labelled colour) — helps to identify venous thrombosis and distinguish veins from arteries. It is useful during the initial planning ultrasound but is usually unhelpful during cannulation.

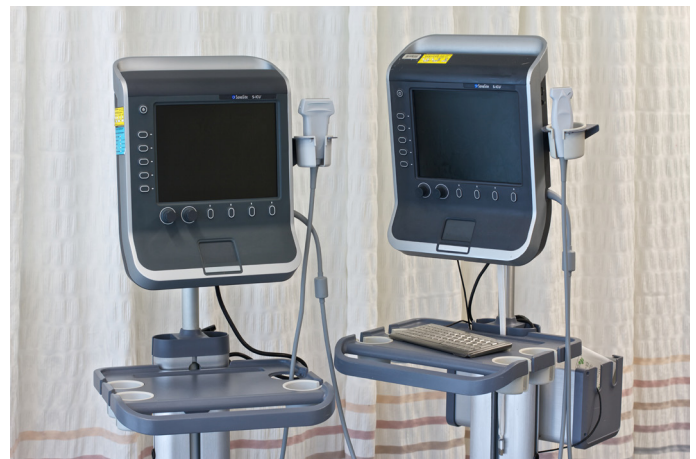

FIGURE 9 Sonosite™ S-Series Ultrasound Machines
Commonly used ultrasound machines for vascular access.

THE EVIDENCE FOR ULTRASOUND GUIDANCE

Ultrasound imaging should be used to plan and guide all central line insertions. A meta-analysis of randomised controlled trials showed that direct ultrasound guidance reduces the rate of failure (relative risk 0.33, CI 0.18–0.45); mechanical complications (relative risk 0.22, CI 0.1–0.45) and multiple attempts before success (relative risk 0.6, CI 0.45–0.79) for central line insertions of the internal jugular and subclavian vein.³¹ A more recent RCT comparing direct ultrasound to landmark guidance for axillary central line insertions found even more strongly in favour of ultrasound guidance. A Cochrane systematic review found 9 RCTs comparing ultrasound versus landmark guided subclavian or axillary CVC insertion showed reduced inadvertent arterial puncture with ultrasound but no difference in any other measured outcome. The same review found 4 RCTs with respect to femoral CVC insertion and concluded higher first-attempt success rate with ultrasound but no difference in complication rate.³²

ULTRASOUND TECHNIQUE

Manipulating the Probe

A scouting ultrasound examination should be performed prior to the procedure to help select the most appropriate site; identify the anatomy and establish the optimal patient position for the procedure. Ultrasound imaging should be used again during the procedure to directly guide cannulation. A sterile probe cover and sterile gel is required for the intra-procedural ultrasound.

Position the ultrasound machine on the opposite side of the patient in your line of view. The less head movement you require to switch between looking at the procedural site and the ultrasound screen, the better.

Hold the ultrasound probe with your non-dominant hand, low, close to the skin with your hand resting on the patient for extra stability. The ultrasound probe can be orientated in line with, for the long axis view (Figure 6), or perpendicular to, for the short axis view (Figure 7), the direction of the target vein. In either case, the centre of the probe should be directed towards the intended puncture point of the vein. When using the short axis view align the probe so that the left side of the probe as you look at it is represented by the left side of the image on screen.

Identifying the Needle

The needle can sometimes be identified by a small echogenic line or circle (Figure 10); or by an acoustic shadow. However, the needle is not always directly visualised on ultrasound and it doesn't need to be, it is more important to visualise the effect of the needle on the soft tissues and vessels that it is penetrating. Deformation of the soft tissues and vessels gives the appearance of 'tenting' on ultrasound (Figure 10). Small longitudinal wiggles of the needle along its axis can help to identify its position. The probability of directly identifying the needle can be improved by keeping the ultrasound beam perpendicular to the needle surface so that sound waves reflected from the needle are directed back towards the probe. When this occurs the probe is said to be 'in plane' with the needle.

DISTINGUISHING VEINS FROM ARTERIES

In comparison to arteries, veins:

- Have thinner walls
- Are less round
- Are more easily compressible
- Have more continuous, less pulsatile flow
- Carry blood flowing towards the heart

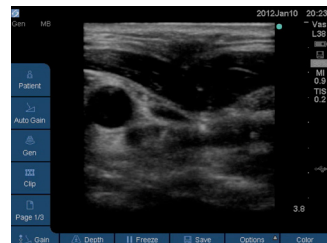

FIGURE 10 Visualising the Needle

A needle tents the sternocleidomastoid muscle and internal jugular vein. The ultrasound probe has been carefully manipulated to be 'in plane' with the end of the needle which is why it is showing as a bright echogenic circle.

Long Axis vs Short Axis

The cross-sectional image generated by the short axis view is better than the long axis view for identifying anatomy. The short axis view also allows for the probe to be tilted at an angle to the skin in line with the direction of the vein — important for meaningful duplex images.

With the long axis view it is possible to visualise the full length of the needle (Figure 12) and even the guide wire as it advances into the vessel (Figure 6). Good quality long axis procedural images are very impressive but can be hard to achieve. Long axis views are intrinsically unstable. Slight rotation or lateral movement of the probe in long axis make dramatic differences to the image attained. In most instances vein and artery lie side by side and the long axis view visualises just one vessel at a time. Worryingly, a small inadvertent lateral movement of the probe towards the artery can lead to accidental arterial puncture.

The procedural challenge in using the short axis view is to keep the probe directed towards the needle tip. There is a tendency to underestimate the depth of the needle if the ultrasound beam is pointed across the needle (Figure 11). Keep in mind the amount of needle you have advanced into the patient and compare this with the apparent depth of the needle on screen.

Prospective randomised trials of novice proceduralists operating on a simulation model at different simulated insertion sites have had conflicting results in terms of speed, ease of use and first-time success rate.³³⁻³⁷ Unfortunately data on more meaningful patient oriented outcomes like complication rates are not available. Subclavian and axillary vein cannulation may be particularly suited to long axis view (see [Finding the Axillary Vein](#)).

With practice it is possible to use the short and long axis views in combination - dynamically rotating the probe during the cannulation to get the advantages of both views. This takes considerable skill and practice. The novice proceduralist should begin with the short axis view.

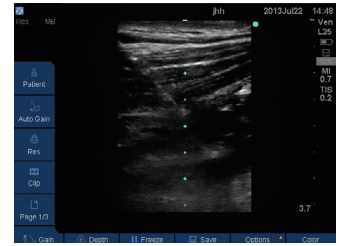


FIGURE 12 Long Axis View

It can be challenging to align the needle, the probe and the vein in 3 dimensions but the result can be ideal full length images of the needle.

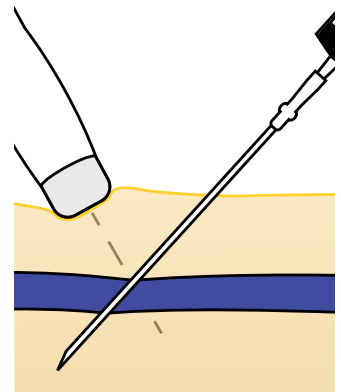


FIGURE 11 Mistaken Needle Depth

There is a tendency to underestimate needle depth when the ultrasound probe is directed towards the shaft rather than the tip of the needle.

ULTRASOUND: KEY POINTS

- Always use ultrasound guidance when available
- Use a high frequency linear probe
- Position the ultrasound machine on the opposite side of the patient from the procedural site
- Hold the ultrasound probe low down, next to the skin
- The short axis view is best for distinguishing vein from artery
- The long axis view requires more practice
- When used well the long axis visualises the full length of the needle
- Aim the ultrasound beam perpendicular to the needle and towards the tip
- Maintain awareness of the needle tip within the patient

Ideal Tip Position

The first concern is to ensure that the catheter is advanced far enough into the vein to avoid extravasation from the most proximal lumen of the catheter into the soft tissues overlying the vein. This is checked at the time of insertion by making sure that blood can be easily aspirated through each of the catheter lumens.

UPPER BODY CENTRAL LINES

Upper body central lines (of the arm, axillary, subclavian and internal jugular veins) require careful tip positioning to prevent later complications. The ideal resting position for the tip is in the superior vena cava (SVC), half way along its length. This puts the tip just above the pericardial reflection. Beyond this, perforation risks tamponade and although rare, is often fatal.³⁸ Unfortunately, retreating distally up the superior vena cava carries other more insidious but equally serious possible complications. When the distal portion of a catheter is in either of the innominate (brachiocephalic) veins there is a risk that the tip will abut the inner wall of the SVC and cause delayed vessel perforation. This is especially true on the left owing to the more acute angle between the left innominate vein and the SVC.¹⁸ High placement also appears to increase the risk of thrombosis.¹⁹

A plain chest X-ray should be performed after each upper body central line to detect pleural injury and confirm position. The carina appears 3½ cm above the lower border of the SVC on a chest X-ray and provides a convenient radiological landmark for the midpoint of the SVC, which is approximately 6 cm long. The tip of the catheter should be within 3 cm of the height of the carina on a chest X-ray (Figure 13).

THINGS TO CHECK ON CHEST RADIOGRAPH

- The tip of the catheter should be within 3 cm of the height of the carina
- The end of the catheter should lie within 40 degrees of the vertical line of the SVC
- Evidence of pleural injury

The chest X-ray is also useful for detecting lines that are abutting the inner wall of the SVC. Laboratory³⁹ and clinical^{18,40} evidence suggests that when the CVC tip is at an angle to the SVC of greater than 40 degrees it is more likely to erode through the vessel wall (Figure 14). When this is detected the line should be repositioned or replaced.

Visceral type chest pain on infusion via the central line is a serious warning that the tip may have perforated a vessel wall.

LOWER BODY (FEMORAL) CENTRAL LINES

Less precision is required to place a lower body central line. The tip should lie anywhere in the IVC. An abdominal X-ray is not required following the routine insertion of a femoral central line.

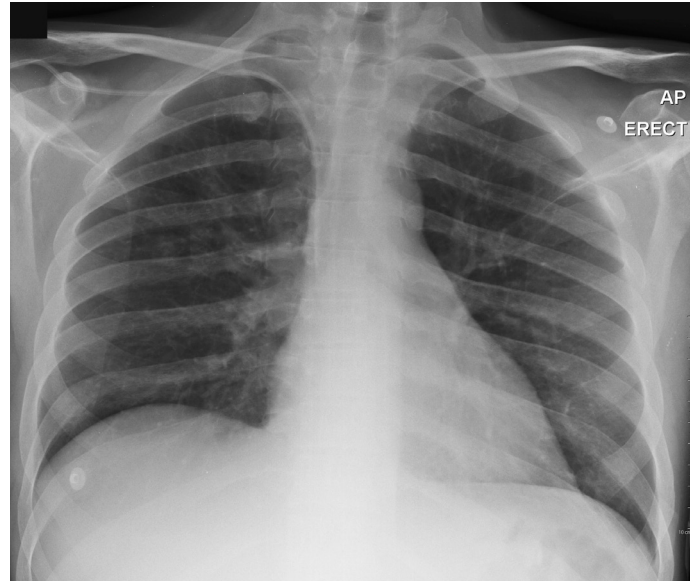


FIGURE 13 Post Insertion Chest X-Ray

This chest X-ray shows a right arm PICC advancing correctly into the superior vena cava. The catheter tip is perfectly in line with the height of the carina, it is lying vertically and there is no evidence of pleural injury.

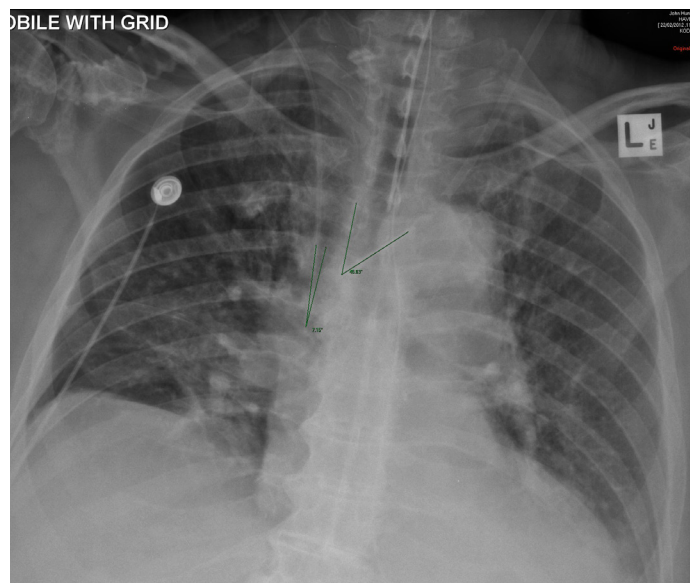


FIGURE 14 Catheter Tip Angles

This rotated mobile chest X-ray shows two central venous catheters. A three lumen CVC is correctly placed in the right internal jugular vein. On the other side of the neck a vascath is placed in the left internal jugular vein. It is about three centimetres above the carina. The digital angle measurements shown on the image show that the vascath tip is approximately 43 degrees from vertical. This is a sign that the vascath has not been advanced far enough and might be abutting the opposing wall of the superior vena cava. However, in this case, the presence of a catheter in the right innominate shows that the vascath is short of the venous junction.

Depth Guide

Taking the time to properly plan catheter depth will prevent catheter repositioning manoeuvres and save you a lot of time in the long run.

Peripherally Inserted Central Catheters

The Arrow™ PICC pack contains a sterile measuring tape that can be used to measure by palpation over the sterile drape. Measure the surface distance from the needle insertion point along the course of the basilic, axillary and subclavian veins to the superior vena cava beneath the sternum at the height of the fourth intercostal space.

Internal Jugular and Subclavian Central Lines

The Peres equations can be used to predict the appropriate depth for an upper body centrally inserted central line based on the patient's height.⁴¹ A subsequent review of the Peres equations found that they perform better than 'one-size-fits-all' approaches but that a small modification of the equation for insertions in the right internal jugular vein was needed (Figure 15).⁴² Be aware that most medical calculators refer to the original rather than the modified Peres equations. 1 to 2 cm of extra depth will be needed when inserting a catheter into the axillary vein as compared with the subclavian vein.

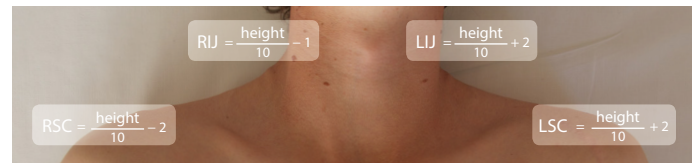


FIGURE 15 Modified Peres Equations

The modified Peres equations provide a reasonably accurate way to predict the appropriate depth to which to advance an upper body CVC. The equations are based on the patient's height in centimetres. RIJ — right internal jugular vein, LIJ — left internal jugular vein, RSC — right subclavian vein, LSC — left subclavian vein.

It is worth considering anomalies in body habitus, thoracic anatomy and needle insertion point in each case. One way to do this formally is to combine the radiological distance between the carina and clavicular notch on plain chest X-ray with the surface anatomy distance from clavicular notch to chosen insertion point.⁴³ This method correctly places the catheter tip within 2 cm of the carina 96% of the time.⁴⁴

Femoral Central lines

A 20 cm or 30 cm long catheter should be inserted into the femoral vein and advanced its full length.

Detecting Arterial Puncture

Arterial puncture is one of the most common complications of central line insertions. When it is recognised early, the needle removed and pressure applied for 5 minutes the consequences are minimal (incidence 2.0–4.5%).⁴⁵ If, on the other hand the artery is dilated and cannulated (incidence 0.1–0.5%),⁴⁵ the consequences include life-threatening haemorrhage and stroke.^{46–48}

Ensure that blood from the introducing needle is non-pulsatile and darkly deoxygenated. Be aware that flow and colour can be unreliable indicators — an incompletely cannulated artery can have low, non-pulsatile flow and arterial blood of a desaturated patient can look quite venous.

When using the catheter-on-needle combination to cannulate the vessel (see 'The Seldinger Technique' below) it is straight forward to remove the needle and transduce the pressure via the catheter to help determine accidental arterial cannulation. Digital manometry can be used but there is a simpler solution. Attach a 50 cm length of intravenous tubing between a small syringe and the intravascular catheter. Fill the syringe by aspiration. Disconnect the syringe, hold the intravenous tubing vertically, and observe the column of blood. A descending column indicates venous placement. An ascending column regardless of respiratory cycle indicates arterial placement. A static column of blood suggests catheter kinking, vessel wall impingement or partial catheter placement in the vessel, in which case, the catheter can be carefully adjusted until continuous flow is demonstrated.⁴⁹

Blood gas analysis on a sample from the vessel can provide another way to delineate vein from artery. In a well oxygenated patient, a partial pressure of oxygen (PO₂) less than 50 mmHg suggests venous blood. In a desaturated patient the venous partial pressure (PvO₂) can be low, in which case, it is helpful to compare blood from the cannulated vessel with blood sampled simultaneously from a confirmed arterial catheter. A PO₂ difference greater than 20 mmHg confirms venous cannulation with 99.7% confidence.⁵⁰

The wire can be fed into the vessel and, before dilating, checked with ultrasound to make sure that it feeds into the vein (Figure 6). However, this is an unreliable check that does not protect against mistaken arteriovenous identification on ultrasound.

WAYS TO CHECK FOR ARTERIAL CANNULATION

- Pressure transduction
- Concurrent blood gas analysis
- Ultrasound

If you are in doubt after these checks, abandon and reattempt the procedure with senior help.

Part 2: Procedure

STEPS

- | | | | |
|---|--|--|----------------------------------|
| 1. Planning | 7. Scrub and gown | 13. Insertion of the wire | 19. Suture or StatLock™ in place |
| 2. Informed consent | 8. Sterile equipment setup | 14. (ultrasound guided) | 20. Clean and dry skin |
| 3. Time out procedure | 9. Site antisepsis | 15. Dilation | 21. Apply dressing |
| 4. Patient preparation wash, shave, position, ultrasound, monitor | 10. Drape | 16. Line insertion over the wire | 22. Chest X-ray |
| 5. Trolley setup | 11. Local anaesthetic infiltration (ultrasound guided) | 17. Aspirate blood and saline flush each lumen | 23. (upper body lines only) |
| 6. Face mask and hair cap | 12. Cannulation and confirmation of venous access | 18. Heparin lock (optional) | 24. Document |

The Seldinger Technique

Begin by preparing the equipment you wish to use. Attach the introducing needle to an empty 10 ml syringe. Small handed proceduralists might be more adept with a 5 ml syringe. It is helpful to align the numbers on the syringe with the bevel of the needle tip so that with the needle tip beneath the skin it is still possible to determine the orientation of the bevel. The needle and syringe should be attached firmly but loosely enough to easily separate with minimal effort. Some proceduralists like to have a small volume of saline in the syringe but dilution of the aspirated venous blood causes it to appear bright red and can cause confusion about the position of the needle.⁵¹

Introducing Needle vs. Catheter-on-Needle

The Arrow™ kit comes with a catheter-on-needle combination (*Figure 16*) that can be used instead of the unsheathed introducing needle. Once the vein has been cannulated the needle can be removed leaving the catheter in place. The guide wire can then be passed through the plastic catheter. The catheter eliminates the risk of snagging the guide wire on the introducing needle and can make it easier to transduce pressures and take blood gas samples to confirm the vessel. The disadvantage of the catheter-on-needle is that it is less rigid and can be harder to manipulate — particularly at the subclavian site and in large patients.

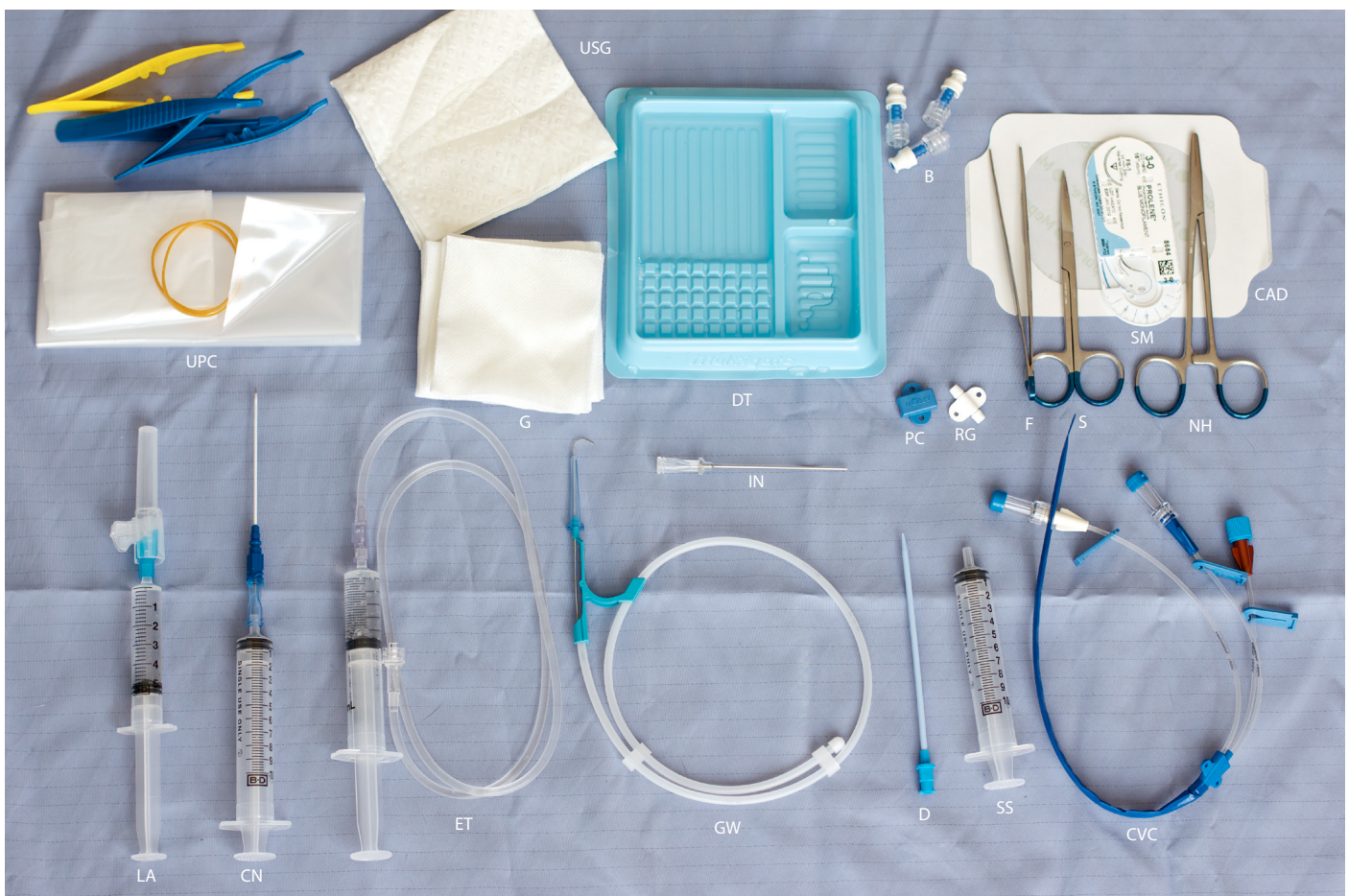

FIGURE 16 Sterile Equipment Setup

LA — local anaesthetic syringe and fine needle, UPC — ultrasound probe cover, USG — ultrasound gel, CN — catheter-on-needle and syringe, IN — alternate introducing needle, ET — saline filled syringe and extension tubing, GW — guide wire in guide wire holder, D — dilator, CVC — central venous catheter, SS — spare syringe, DT — dressing tray, G — gauze, B — bungs, RG — rubber grip, PC — plastic clamp, SM — suture needle and material, NH — needle holders, F — forceps, S — scissors, CAD — clear adhesive dressing.

Prepare the wire. Remove the white plastic cap and slide the wire in and out of the plastic guide wire holder to loosen it. Take note of the orientation of the J-tip of the wire. Retract the wire into the plastic snail so that the tip is just protruding and the bend in the wire is straightened. Place the wire on the drapes within convenient reach.

3 SYRINGES

- 5 ml syringe filled with lignocaine
- 10 or 5 ml empty syringe attached to the introducing needle
- 10 ml syringe filled with saline for flushing

A 5 ml syringe should be used for the lignocaine to help distinguish it from the 10 ml saline flushing syringe and avoid accidental intravenous lignocaine injection. Under direct ultrasound guidance infiltrate the soft tissues overlying the target vein with 5 ml of 1% lignocaine. You may see separation of tissues on the ultrasound image as the local anaesthetic is injected.

Place the introducing needle at the skin distal to the ultrasound probe at an angle of 45 degrees to the skin pointing in line with the vein proximally towards the ultrasound probe. The needle should be at a distance from the ultrasound probe such that as it is advanced the needle will intersect with the vein directly below the probe. Deeper vessels will require larger separation between probe and needle.

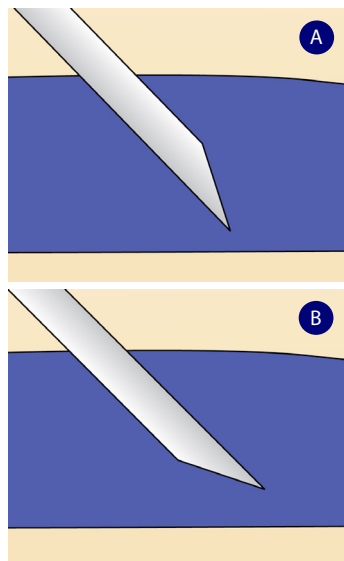


FIGURE 17 Bevel Orientation

It is common practice to insert the needle with the bevel facing up (A). Inserting the needle bevel facing down may cause less injury to the posterior venous wall (B).

It is common practice to insert the needle with the bevel facing up but one small study⁵² showed a lower incidence of posterior vein wall haematoma when the bevel is inserted face down (Figure 17).

Advance the introducing needle, aspirating gently as you go. Watch carefully for a flashback of venous blood. The pressure of the advancing needle will deform the soft tissues and often completely occlude the target vein. When this happens it is common to pass right through the vein without a flashback. This is not a problem. Slowly withdraw the needle while aspirating. The traction will open the vein and provide a flashback of blood when the needle tip reaches back into the vein lumen. Set the ultrasound probe aside and instead use your non-dominant hand to secure and anchor the needle to the patient.

Ensure easy aspiration of blood. Remove the syringe from the introducing needle. Venous blood should drip slowly from the needle hub. The Arrow™ kit comes with a hollow blue raulerson syringe designed to allow the guide wire to pass down its length into the needle without disconnection

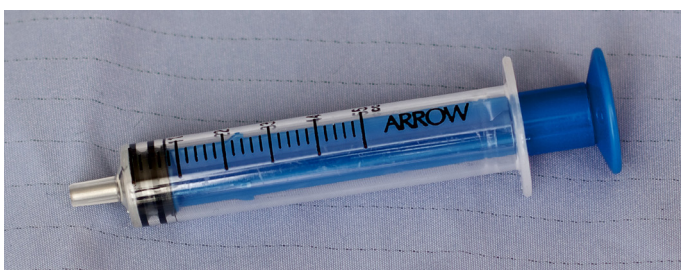

FIGURE 18 Raulerson Syringe

The plunger of a raulerson syringe has an internal channel through which to pass the guide wire. In theory this might avoid the need to disconnect the syringe from the introducing needle or catheter.

(Figure 18). However, this disconnection is a vital last opportunity to prevent an accidental arterial dilatation and catheterisation (see 'Detecting Arterial Puncture' above). The somewhat cumbersome raulerson syringe is best avoided.

Once you are satisfied that you have appropriate venous access feed the wire into the needle hub. The wire protrudes from the tip of the needle as the 10 cm mark passes over the pinch mark on the guide wire holder. If you meet with resistance at the 10 cm mark, the implication is that the needle tip is no longer cleanly inside the vein. Remove the wire and reattach the syringe. Make small adjustments to the needle whilst aspirating on the syringe to re-establish the needle in the vein and reattempt to feed the wire. Sometimes adjusting the needle and syringe to be at a shallower angle to the vein will help the wire pass more easily. The wire has a J-tip at its leading end. Try orientating the wire such that the J-tip bends up through the bevel of the needle (Figure 19). This might involve a 180 degree rotation of your dominant, guide wire holding hand. If you encounter resistance to the wire beyond the 10 cm mark you are meeting an obstruction within the vessel beyond the needle. Rotating the wire as you advance can help the J-tip of the wire negotiate tortuosities in the vein. You should be able to pass the wire freely 20 cm into the vein with minimal resistance. Excessive force on the wire can perforate the great

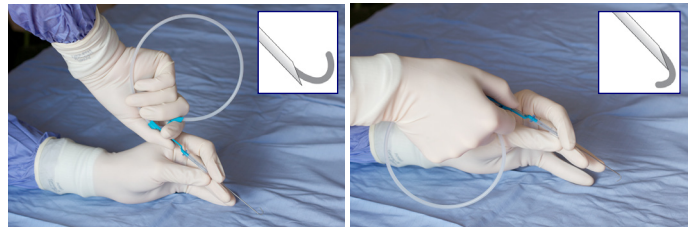

FIGURE 19 Guide Wire Orientation

Sometimes resistance will disappear when the guide wire holder is rotated through 180 degrees to alter the orientation of the J' tip as it passes out of the needle / catheter.

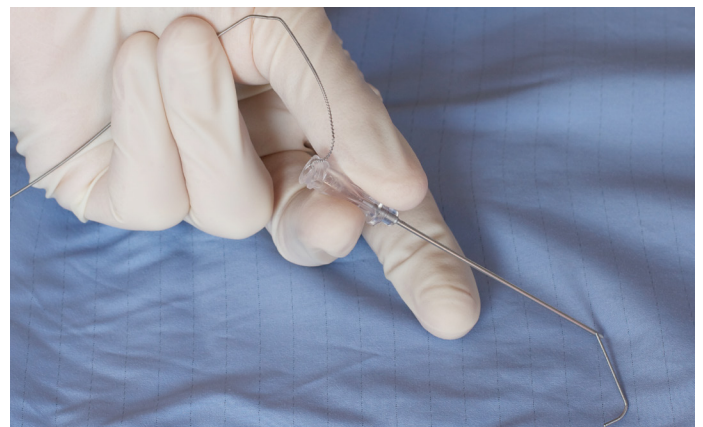


FIGURE 20 Fractured Guide Wire

The guide wire can catch and unravel on the needle aperture if it is retracted back through the needle.

veins with dire consequences. Do not withdraw the guide wire back through an introducing needle — it can catch on the needle aperture and unravel (Figure 20). If you are having difficulty passing the wire, it is likely safer to abandon the procedure, remove the needle and wire together and reattempt at another site with senior help.

If the guide wire is advanced too far it can cause arrhythmias by irritating the myocardium. Atrial ectopics are common and resolve when the wire is retracted. More malignant rhythms are rare, but have been described. This is the reason that patients undergoing central line insertions should have ECG monitoring.

Remove the needle from the patient being careful to maintain the wire at a constant depth. Use your non-dominant hand to secure the wire. Pass the dilator over the wire. Rotate the dilator in one continuous direction as it passes through the skin. It is key to hold the dilator low down next to




FIGURE 21 Burred Dilator

Advancing the dilator at too flat an angle is a common mistake. The guide wire kinks and burrs the dilator.

the skin. Be patient and avoid excessive force, a good dilation technique takes time. Be careful to keep the dilator in the plane of the tract you created with the introducing needle. A common mistake is to advance the dilator at too shallow an angle resulting in a kinked or fractured guide wire and a burred dilator (*Figure 21*). Aim to advance the dilator slightly deeper than was necessary with the introducing needle.

In some patients it will be necessary to make a small incision in the skin away from the wire to facilitate insertion of the dilator but the cut often continues to bleed for some time after the procedure and can compromise the dressing. With good dilator technique the incision is unnecessary in most patients.

Remove the dilator whilst continuing to maintain the wire at a constant depth. Ensure that the distal lumen of the central line is unclamped and feed the distal lumen of the central line over the wire. It is imperative to keep hold of the wire with at least one hand the whole time that the wire is in the patient. A surprisingly common and easily avoided mistake is to let go of the wire, become preoccupied with the catheter and advance the wire into the patient along with the catheter. A lost wire requires

urgent surgical or radiological retrieval to prevent disastrous vascular and myocardial trauma. With careful control of the wire advance the catheter to the appropriate depth as indicated by the measurement markings on the catheter. Remove the wire and ensure that it is intact with the J-tip at its end. Make a mental note and confirm with your assistant that you have removed the wire.

Aspirate and flush each lumen with saline to confirm it communicates with the vein. This must be done using a 10 ml syringe. Smaller syringes are prone to generate high pressures and rupture the catheter if there is an obstruction. Vascaths should be carefully filled with high concentration heparin (25 000 units in 5 mL) to prevent thrombosis. The volume required, usually between 1 and 2 ml, is indicated on each lumen. Because of the need to administer precise small volumes, a 3 ml syringe should be used to administer the heparin. The 3 ml syringe must only be used after checking the lumens with a 10 ml syringe.

KEY POINTS

- The catheter-on-needle combination is a useful alternative to the larger uncovered introducing needle
- Align the needle bevel with the numbers on the syringe
- Place the guide wire on the drapes within easy reach
- Do not withdraw the guide wire back through the needle bevel
- The Arrow™ hollow blue syringe is best avoided
- Keep an eye on the ECG trace while the guide wire is within the patient
- Try gently rotating the guide wire to help it negotiate venous tortuosities
- Hold the dilator low down next to the skin and rotate it in a continuous direction
- It is possible to pass the dilator without making a skin incision in most patients
- Unclamp the distal CVC lumen before trying to pass it over the guide wire
- Keep hold of the guide wire the whole time it is within the patient
- Aspirate and flush each CVC lumen with a 10 ml syringe to ensure it communicates with the vein

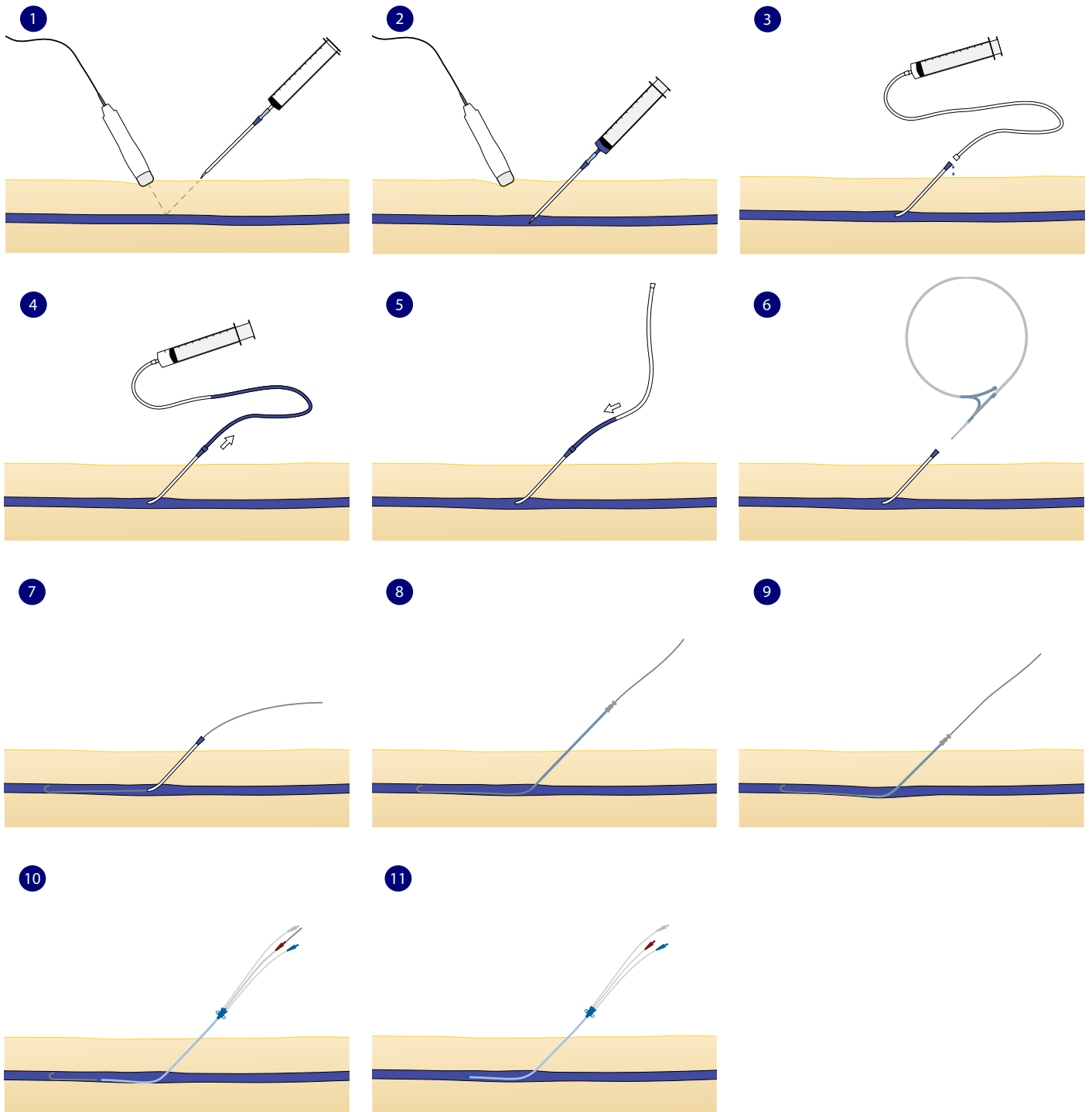


FIGURE 22 The Seldinger technique

The vein is cannulated under direct ultrasound guidance (1–2). The catheter is fed into the vein and the needle is removed (3). Blood is aspirated into the saline filled extension tubing (4). The syringe is disconnected from the extension tubing to confirm venous placement (5). The guide wire is fed through the catheter into the vein (6–7). A tract around the guide wire is dilated (8 & 9). The catheter is fed into the vein over the guide wire, which is then removed (10 & 11).

Internal Jugular Vein

Anatomy

The internal jugular (IJ) vein is a continuation of the sigmoid sinus at the base of the brain. The internal jugular exits the skull inferiorly through the jugular foramen and travels inferiorly with the carotid artery and vagus nerve in the carotid sheath towards the ipsilateral clavicular head. At the jugular foramen the IJ lies posteriorly to the carotid artery. Further inferiorly the vein lies laterally to the artery. At the level of the clavicle there is some separation between vein and artery (*Figure 23*). The carotid sheath lies beneath the sternocleidomastoid, omohyoid and sternothyroid muscles at a relatively shallow depth in most patients (2–3 cm).

Position

A patient who is intravascularly dry or non-ventilated and in respiratory distress can generate large negative venous pressures on inspiration. These negative pressures can draw in a large air embolus through the introducing needle while it is in the vein. The best means of prevention is to lie the patient in the Trendelenburg position — supine with 15–30 degrees of head down tilt. In addition to reducing the risk of air embolism this increases the diameter of the internal jugular vein.^{53–55}

The Trendelenburg position is much less important in intubated patients receiving positive pressure ventilation.⁵⁶ In some intubated patients,

notably those with raised intracranial pressure or severe respiratory failure, it is advisable to avoid the Trendelenburg position. Another reasonable situation in which to avoid the Trendelenburg position is in patients with pulmonary oedema and demonstrably raised venous pressures.

Once the patient is in an optimal position use the ultrasound to ensure that there is minimal variation in vein diameter with the ventilatory cycle. If you suspect that the risk of air embolus is high consider inserting femoral or basilic vein catheter instead.

A small degree of head rotation (10–20 degrees) away from the midline towards the contralateral side may be necessary to gain manual access to the neck. However, more extreme rotation should be avoided as it reduces the size of the vein and the separation between artery and vein.^{57–59}

Finding the Internal Jugular Vein

Three approaches to the IJ are described in the literature (anterior, central and posterior). The central approach, described in this guide, is the best suited to ultrasound guidance. The ultrasound probe is placed over the sternocleidomastoid muscle just inferior to the midpoint between the sternal head and the mastoid process. The needle is advanced through the sternocleidomastoid and into the vein below.

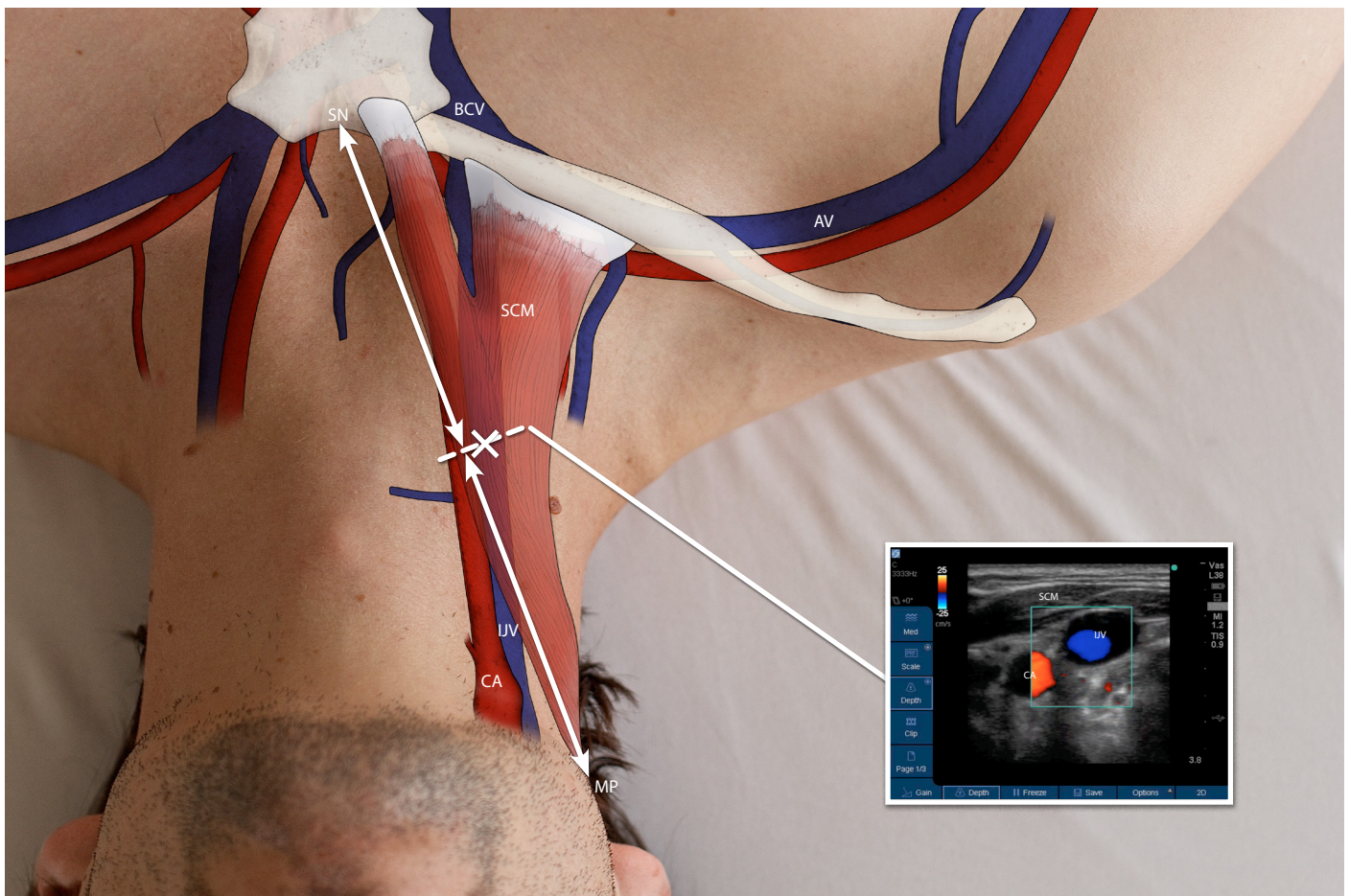


FIGURE 23 Internal Jugular Vein Surface Anatomy

IJV — internal jugular vein, CA — carotid artery, BCV — brachiocephalic vein, AV — axillary vein, SCM — sternocleidomastoid muscle, SN — sternal notch, MP — mastoid process.

Subclavian and Axillary Veins

Anatomy

The axillary vein is a continuation of the basilic vein. It begins deep in the axilla at the lateral border of the teres major muscle. It runs anteriorly, superiorly and medially towards the gap between the clavicle and first rib. The axillary vein passes underneath the clavicle at the clavicular bend. The clavicular bend is easily palpable on the anterior border of the clavicle between the lateral one third and medial two thirds of the bone's length. The axillary vein becomes the subclavian vein as it passes over the lateral border of the first rib. The subclavian vein runs up over the first rib and then inferiorly towards its junction with the internal jugular and thoracic duct where it becomes the innominate vein. The subclavian vein is more superficial and is in closer proximity to the pleura than the axillary vein. The axillary and subclavian arteries lie posterior-superiorly to their companion veins.

Position

Lie the patient in the Trendelenburg position (flat with 20 degrees of head down tilt). Unlike the internal jugular vein this does not increase the diameter of the subclavian vein⁶⁰ but it does help avoid air embolus (see above). A folded towel between the scapulae helps to retract the shoulder and enlarge the procedural field.⁶¹

Approach

The clavicle hides most of the subclavian vein from ultrasound view. To overcome this, the cannulation occurs more laterally into the deeper axillary vein. Ultrasound guided infraclavicular catheterisation of the subclavian vein is in fact catheterisation of the axillary vein³² (this distinction is often ignored in the published literature and clinical communication).

Finding the Axillary Vein

With the ultrasound probe identify the subclavian vein as it passes directly below the clavicular bend. Follow the subclavian distally away from the clavicle as it travels over the first rib to become the axillary vein. The skin insertion point should be about 4 cm lateral to the mid clavicular point to allow enough room for the ultrasound probe to visualise the cannulation. At this position the vein is

deeper and requires a steeper angle (45 degrees) of approach with the needle than is required in the traditional landmark approach (almost flat). The axillary vein is further from the pleura than the subclavian but at this angle of approach there is still considerable risk of pleural injury. It is imperative to maintain ultrasound visualisation of the needle tip throughout the procedure to avoid accidental pleural injury.

In theory, the long axis view's ability to visualise the full length of the needle makes it especially suited to axillary vein cannulation given the risk of pleural injury. A manikin³⁶ and an observational patient study⁶² found a higher first-time success rate with the long axis view while a randomised controlled trial found the opposite.⁶³ Unfortunately, no study has been powered to find a difference in pneumothorax rates, the topic of most interest.

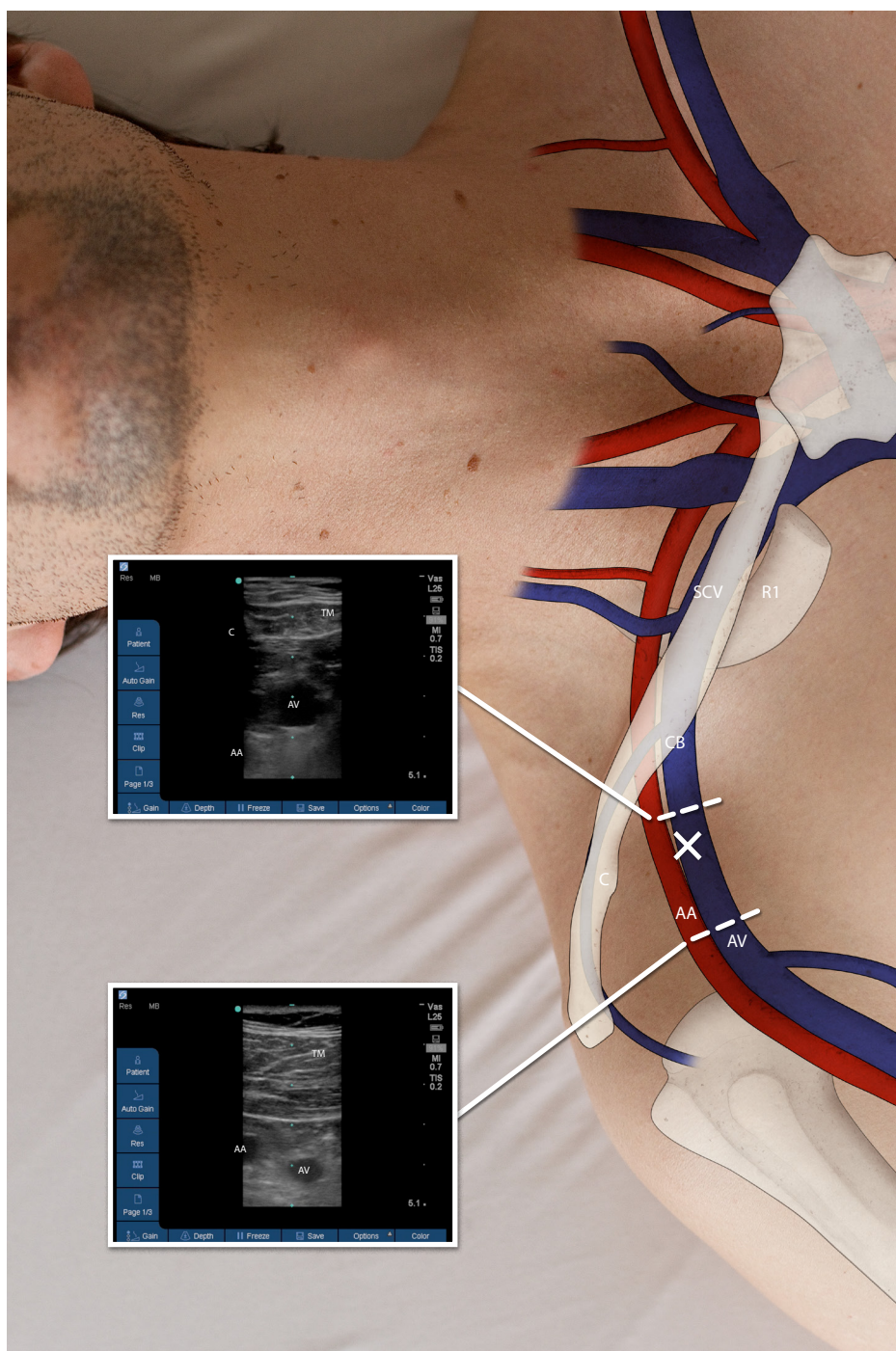


FIGURE 24 Subclavian and Axillary Vein Surface Anatomy

AV — axillary vein, AA — axillary artery, SCV — subclavian vein, C — clavicle, CB — clavicular bend, R1 — first rib, TM — teres minor.

Femoral Vein

Anatomy

The femoral vein runs inferiorly through the femoral triangle, an area on the anterior upper leg bound superiorly by the inguinal ligament; laterally by the sartorius muscle and medially by the medial border of the adductor longus muscle. The floor of the femoral triangle is formed by the iliopsoas and pectineus muscles. Near the inferior border of the femoral triangle the femoral vein is joined by two major veins: the great saphenous medially and the profunda femoris posterior-laterally. Near the superior border of the femoral triangle, at around the height of the inguinal ligament the femoral vein is joined anteriorly by the superficial epigastric vein. The ideal point for catheter insertion is in between these junctions at the midpoint between the inguinal ligament superiorly and the branch of the deep saphenous vein inferiorly. Superior to this point, the femoral vein runs more deeply to become the inguinal vein and accessing the vein becomes more difficult; and inferiorly from this point it is common for the superficial femoral artery to overlie the femoral vein raising the risk of arterial puncture (Figure 25).

A high rate of mechanical complications and the lack of reliable surface anatomy landmarks makes ultrasound guidance particularly important. Anatomically guided techniques rely on the femoral vein being just medial to the point of maximal pulsation in the femoral triangle. Unfortunately, this can be misleading, in some individuals the point of maximal pulsation arises from the superficial rather than the common femoral artery.

Position

The proceduralist should stand on the ipsilateral side of the patient. The patient should be lying flat but not necessarily horizontally. The femoral canal can be made more accessible by externally rotating the leg and placing a folded towel under the ipsilateral buttock to slightly extend the hip.

Finding the Femoral Vein

The ultrasound probe is placed on the patient just below the inguinal ligament at a distance from the inside leg that is in line with the midpoint between the pubic symphysis and the anterior superior iliac crest.

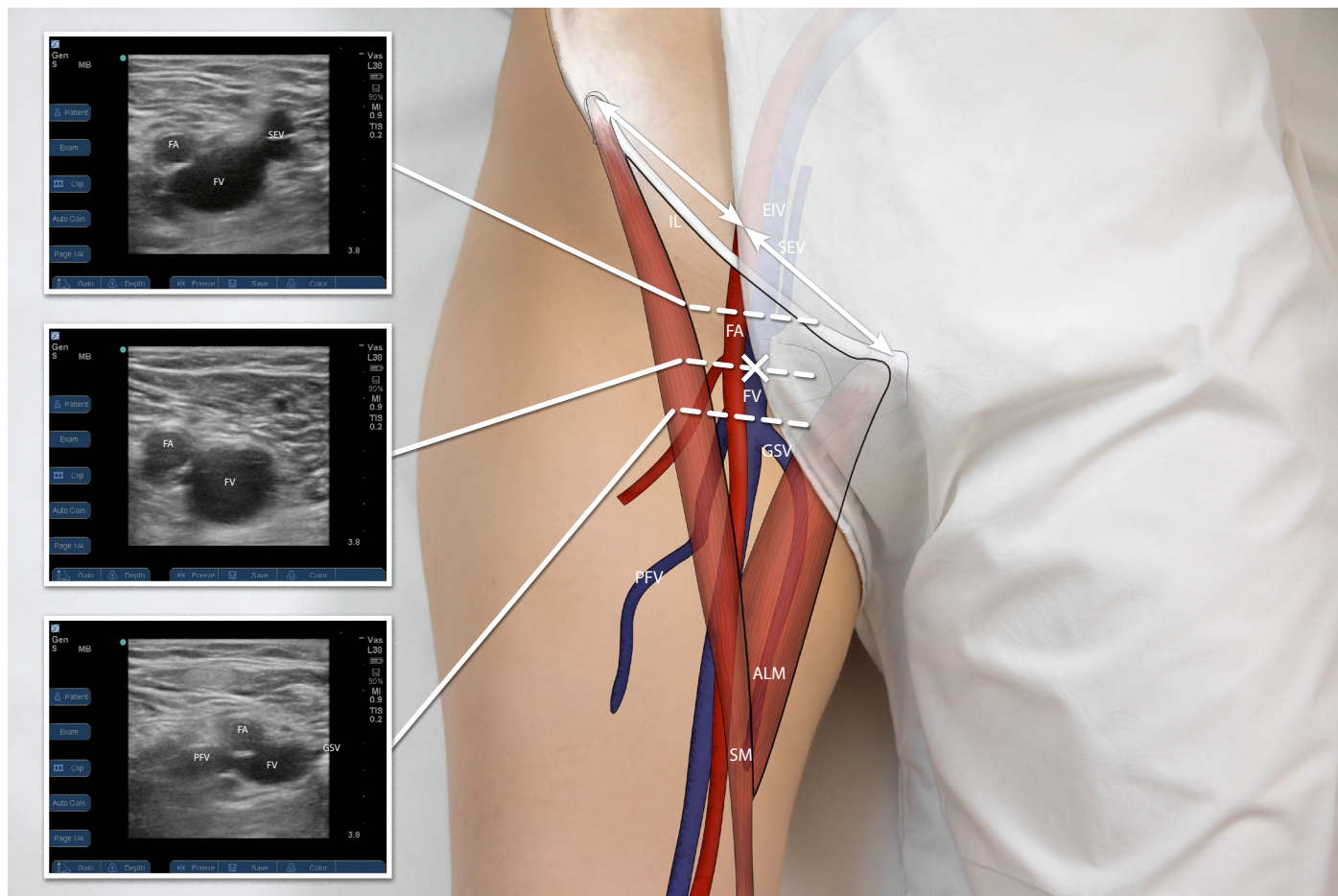


FIGURE 25 Femoral Vein Surface Anatomy

FV — femoral vein, FA — femoral artery, EIV — external iliac vein, SEV — superficial epigastric vein, PFV — profunda femoris vein, GSV — great saphenous vein, IL — inguinal ligament, ALM — adductor longus muscle, SM — sartorius muscle. Black outline depicts femoral triangle.

Peripherally Inserted Central Catheter (PICC)

Anatomy

The forearm is served by a network of veins that drain into the three major veins of the upper arm: the basilic, brachial and cephalic. PICC insertion can be dishearteningly difficult. The key is distinguishing the basilic vein.

The basilic vein runs from the posterior medial aspect of the forearm up and around to the anterior medial aspect of the cubital fossa where it is joined by the median cubital vein. Near the border of the middle and inferior thirds of the upper arm it passes deep to the brachial fascia and travels superiorly on the medial surface of the humerus in proximity to the brachial artery, brachial veins, ulnar nerve and median nerve. The basilic vein continues as the axillary vein in the axilla. The basilic is the largest vein of the upper arm. This and its straight course into the axillary vein make it the most suitable vein for a PICC.

The brachial vein is comprised of two small venae comitantes. These vessels and their connections entwine the brachial artery in an anastomotic network. Not uncommonly, the deep brachial veins join to form one brachial vein for parts of their course up the arm. The complex course and of the brachial veins and their small calibre can make them difficult to feed a catheter through.

The cephalic vein flows up the anterior-lateral upper arm on the surface of the biceps. It is often the most superficial and visible vein of the cubital fossa which makes it a tempting target for PICC insertion. However, the cephalic is problematic. It empties into the axillary vein at an oblique angle that causes difficulty when feeding a catheter (Figure 26). Cannulation of the cephalic vein is also associated with a significantly higher incidence of thrombosis as compared to the basilic vein (57% vs 14% in an observational study).⁶

Position

The patient can be lying in bed or reclined on a chair. Either way, it helps to have the patient's arm somewhat abducted to the side and resting on a support to allow easy access to the medial aspect of the arm.

Modified Seldinger Technique

The basilic vein is visualised with ultrasound just proximal to the antecubital fossa. Owing to the length and narrow calibre of PICCs a slightly different technique is used for insertion, often referred to as the modified Seldinger technique.

This guide describes the insertion of the Arrow™ PICC. You may also encounter Groshong™ PICCs, which are finer, more flexible and, unlike the Arrow PICC, contain a stiffening wire that must be removed after catheter placement.

Place and tighten a tourniquet on the upper arm. Using direct ultrasound guidance cannulate the vein with the supplied introducing needle or peripheral intravenous catheter (20 gauge or larger). Have your non-sterile assistant

reach under the drapes to release the tourniquet. Feed the guide wire carefully into the vein with the soft flexible tip first. The wire must **never** be advanced with the stiff end first. Remove the needle or IV catheter leaving the wire in place. A partially split sheath is supplied ready loaded on a dilator. Feed this sheath and dilator combination as one over the wire carefully through the soft tissues and into the vein. Continuous rotation in one direction helps the advance. The dilator should feed easily to the hub once it is in the vein. Difficulty advancing can be a sign of misplacement, stenosis or thrombosis. Ultrasound can help identify the issue. Remove the dilator and wire together leaving the sheath in the vein. Feed the PICC into the sheath. The PICC is soft and flexible. Small advancing motions are more successful than long ones. As you advance the PICC have the patient bend his or her head to the side you are working on

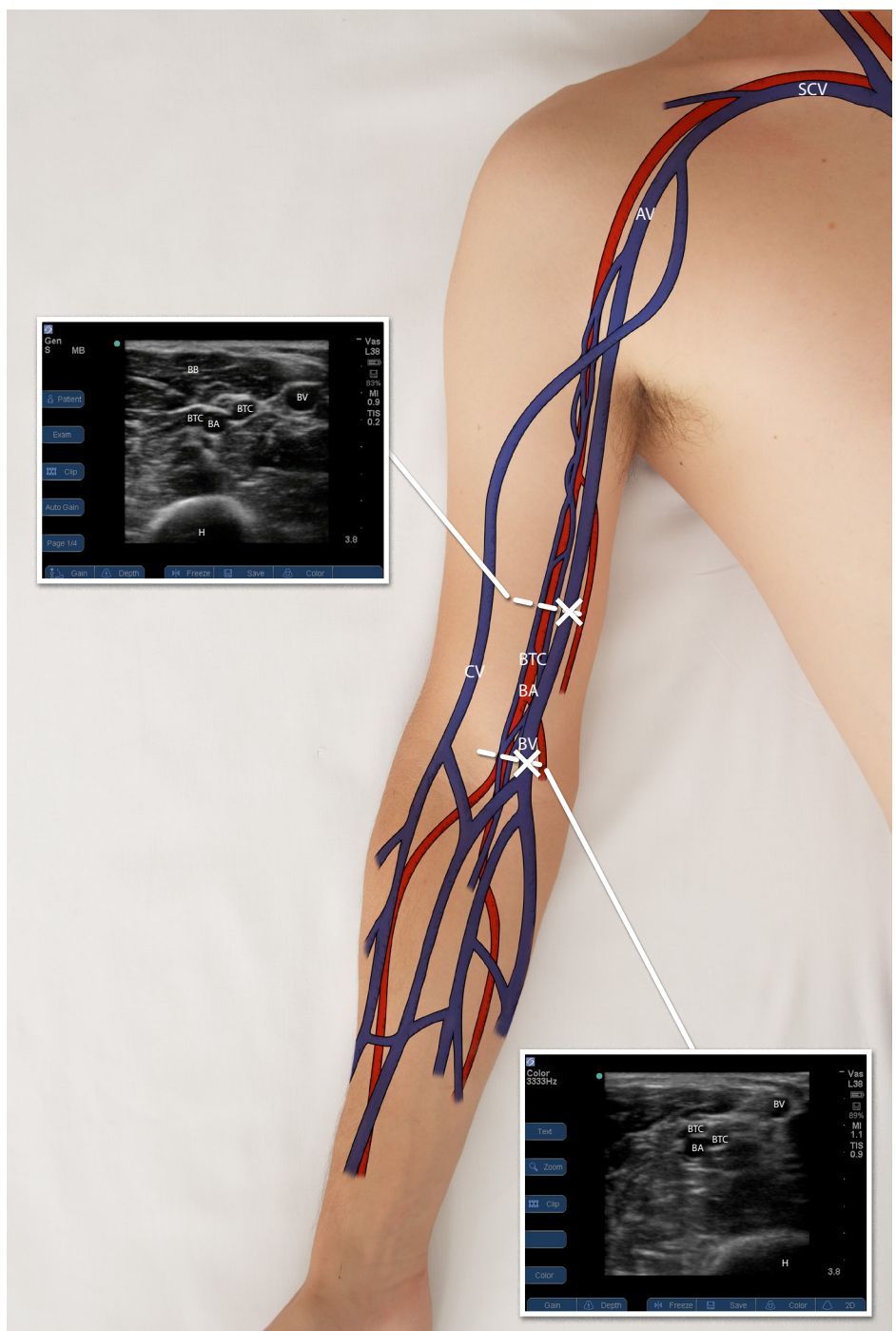


Figure 26 Arm Veins

BV — basilic vein, BVC — brachial venae comitantes, CV — cephalic vein, AV — axillary vein, SCV — subclavian vein, BA — brachial artery, H — humerus, BB — biceps brachii.

and touch ear to shoulder. This manoeuvre closes the angle between the subclavian and internal jugular veins and helps to prevent cannulation of the internal jugular vein.

the arm with various degrees of adduction, rotation and traction. While you are manipulating the arm take care not to compromise the sterile drape. Once the PICC is at the pre-planned depth (see [Depth Guide](#)) split the sheath at its hub and peel it out of the patient.

One of the most common problems is resistance feeding the wire through the axilla. It can be overcome with a bit of persistence by repositioning

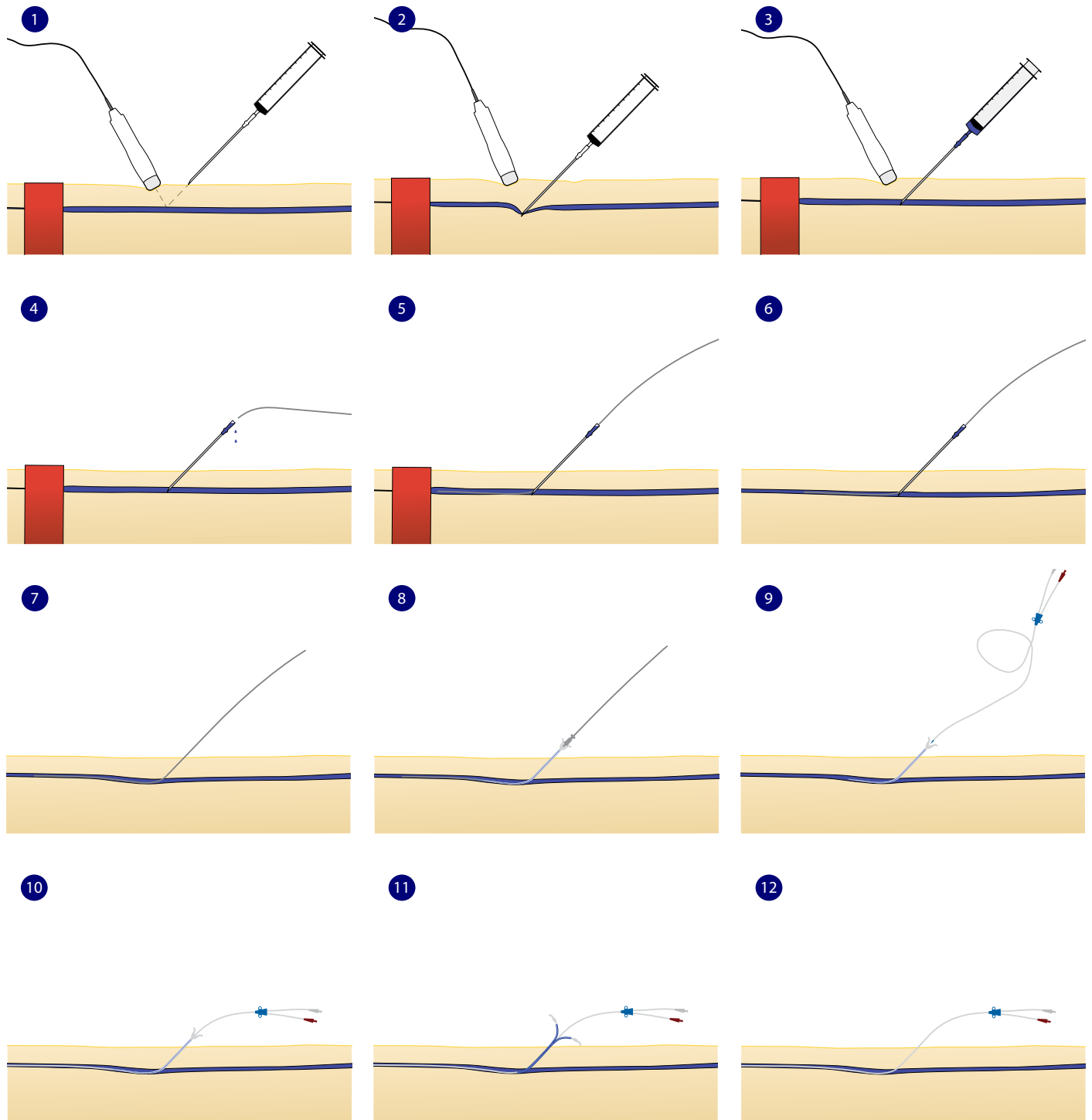


FIGURE 27 The Modified Seldinger Technique

A tourniquet is placed around the upper arm to dilate the basilic vein (1). The vein is cannulated (1–4). A floppy tipped straight guide wire is fed into the vein (5 & 6). A combined dilator and split catheter is fed over the wire into the vein (7 & 8). The dilator and wire are removed leaving the split catheter through which to railroad the PICC (9). The split catheter is snapped open at the hub and peeled away (11, 12).

Securing and Dressing the Line

Vascaths at any site require 2 sutures. Non-vascath central catheters in the internal jugular and femoral veins require 4 sutures (Figure 32). Subclavian and peripherally inserted catheters are secured by a proximal and distal StatLock™ (Figure 32) instead of sutures.

With the exception of vascaths, central venous catheters are supplied with a soft white rubber grip and blue plastic cover that needs to be clamped around the catheter about 1 cm from the skin (Figure 29). A suture is tied through each of the eyelets and then, separately, the skin. Further sutures are placed through each of the two eyelets in the catheter hub where the lumens separate. An infiltration of 1% lignocaine is necessary to anaesthetise for the sutures.

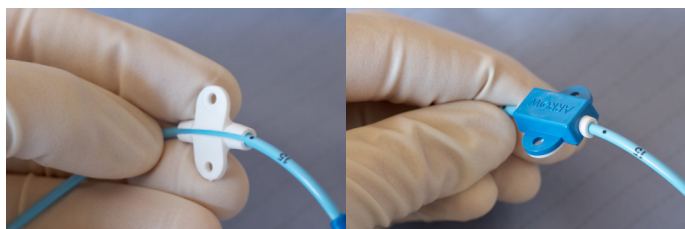


FIGURE 29 Catheter Grip and Clamp

The white rubber grip is applied around the catheter next to the insertion point. The blue plastic clamp then fits around the grip to hold it in place. The eyelets of the grip and clamp should line up ready to be sutured to the skin or fitted into a StatLock™.

At each attachment point there should be separate suture loops through the skin and catheter eyelet (Figure 28). The skin loop should sit firmly without pinching the skin. Very tight central line sutures can cause a surprisingly large blood loss and even cut themselves loose. 3-0 is the thinnest suture material that should be used to secure a central line and a thicker suture material should be used for patients with fragile skin. Prolene™ (polypropylene) is our standard choice of suture material. It is unbraided to reduce the risk of infection but it is prone to unravel. To avoid this each knot requires 6 opposing throws and 1 cm of spare thread on each end.

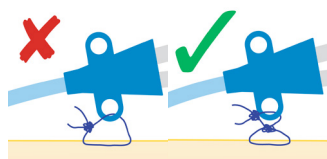


Figure 28 Catheter Sutures

Catheters should be sutured in a figure-of-8 with two knots.

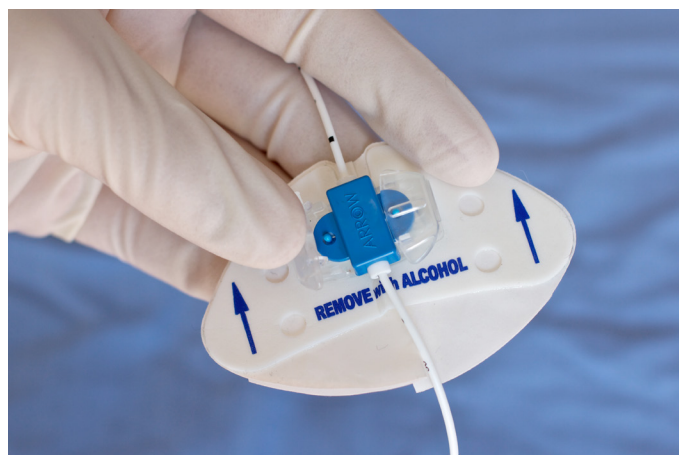

FIGURE 30 StatLock™

Catheter grip and clamp set in a StatLock™ ready to be applied to the skin.

StatLocks™ are adhesive fixtures that replace sutures. Each StatLock™ has two small plastic pins that fit the eyelets in the catheter hub and proximal rubber grip. A plastic door in the StatLock™ clips closed over the catheter to hold it in place (Figure 30). Once the StatLocks are secured to the catheter, prep the skin with the adhesive skin wipes provided, peel off the adhesive backing and secure the StatLocks to the patient's skin.

Clean the site around the secured catheter with sterile saline and dry the skin with gauze. Apply a clear, impervious adhesive dressing, such as Mepore™, over the catheter. The skin can be swabbed with benzoin resin in alcohol (Figure 31) to make the dressing more adherent to the skin. Provide slack in the dressing as you apply it to avoid tenting around skin creases.



FIGURE 31 Friars' Balsam

Benzoin resin can improve skin-to-dressing adhesion.

Internal Jugular	Femoral	Axillary & Subclavian	PICC	Vascath at any site
4 sutures	4 sutures	2 StatLocks™	2 StatLocks™	2 sutures
				

FIGURE 32 CVC Securing Mechanisms

CVC are fixed to skin with either sutures or a StatLock™ depending on site and type of catheter.

References

1. Sznajder JI, Zveibil FR, Bitterman H, Weiner P, Bursztein S. Central vein catheterization. Failure and complication rates by three percutaneous approaches. *Arch Intern Med* 1986 Feb;146(2):259–61.
2. Raad II, Hohn DC, Gilbreath BJ, Suleiman N, Hill LA, Brusco PA, et al. Prevention of central venous catheter-related infections by using maximal sterile barrier precautions during insertion. *Infect Control Hosp Epidemiol* 1994 Apr;15(4 Pt 1):231–8.
3. Evans RS, Sharp JH, Linford LH, Lloyd JF, Tripp JS, Jones JP, et al. Risk of Symptomatic DVT Associated With Peripherally Inserted Central Catheters. *Chest* 2010 Oct 1;138(4):803–810.
4. Turcotte S, Dubé S, Beauchamp G. Peripherally inserted central venous catheters are not superior to central venous catheters in the acute care of surgical patients on the ward. *World J Surg* 2006 Aug;30(8):1605–19.
5. Pikwer A, Åkeson J, Lindgren S. Complications associated with peripheral or central routes for central venous cannulation. *Anaesthesia* 2012 Jan;67(1):65–71.
6. Allen AW, Megargell JL, Brown DB, Lynch FC, Singh H, Singh Y, et al. Venous thrombosis associated with the placement of peripherally inserted central catheters. *J Vasc Interv Radiol* 2000 Dec;11(10):1309–14.
7. Timsit J-F, Misset B, Carlet J, Boyer J-M, Farkas J-C, Martin J-B, et al. Central Vein Catheter-Related Thrombosis in Intensive Care Patients Incidence, Risks Factors, and Relationship With Catheter-Related Sepsis. *Chest* 1998 Jul 1;114(1):207–13.
8. Cowl CT, Weinstock JV, Al-Jurf A, Ephgrave K, Murray JA, Dillon K. Complications and cost associated with parenteral nutrition delivered to hospitalized patients through either subclavian or peripherally-inserted central catheters. *Clin Nutr* 2000 Aug;19(4):237–43.
9. Safdar N, Maki DG. Risk of catheter-related bloodstream infection with peripherally inserted central venous catheters used in hospitalized patients. *Chest* 2005 Aug;128(2):489–95.
10. Merrer J, De Jonghe B, Golliot F, Lefrant JY, Raffy B, Barre E, et al. Complications of femoral and subclavian venous catheterization in critically ill patients: a randomized controlled trial. *JAMA* 2001 Aug 8;286(6):700–7.
11. Parienti JJ, Mongardon N, Mégarbane B, Mira JP, Kalfon P, Gros A, et al. Intravascular Complications of Central Venous Catheterization by Insertion Site. *N Engl J Med* 2015 373(13), 1220–1229.
12. Timsit J-F. Central venous access in intensive care unit patients: is the subclavian vein the royal route? *Intensive Care Med* 2002 Aug;28(8):1006–8.
13. Schillinger F, Schillinger D, Montagnac R, Milcent T. Post catheterisation vein stenosis in haemodialysis: comparative angiographic study of 50 subclavian and 50 internal jugular accesses. *Nephrol Dial Transplant* 1991;6(10):722–4.
14. Untracht SH. Axillary artery as a landmark in cannulating the subclavian vein. *Surg Gynecol Obstet* 1988 Jun;166(6):565–6.
15. Hilty WM, Hudson PA, Levitt MA, Hall JB. Real-time ultrasound-guided femoral vein catheterization during cardiopulmonary resuscitation. *Ann Emerg Med*. 1997 Mar;29(3):331–336; discussion 337.
16. Marelich GP, Tharratt RS. Greenfield inferior vena cava filter dislodged during central venous catheter placement. *Chest* 1994 Sep;106(3):957–9.
17. Mukau L, Talamini MA, Sitzmann JV. Risk factors for central venous catheter-related vascular erosions. *JPEN J Parenter Enteral Nutr* 1991 Oct;15(5):513–6.
18. Duntley P, Siever J, Korwes ML, Harpel K, Hefner JE. Vascular erosion by central venous catheters. Clinical features and outcome. *Chest*. 1992 Jun;101(6):1633–8.
19. Puel V, Caudry M, Le Métayer P, Baste JC, Midy D, Marsault C, et al. Superior vena cava thrombosis related to catheter malposition in cancer chemotherapy given through implanted ports. *Cancer* 1993 Oct 1;72(7):2248–52.
20. Ishizuka M, Nagata H, Takagi K, Kubota K. Right internal jugular vein is recommended for central venous catheterization. *J Invest Surg* 2010 Apr;23(2):110–4.
21. Teichgraber UKM, Nibbe L, Gebauer B, Wagner H-J. Inadvertent puncture of the thoracic duct during attempted central venous catheter placement. *Cardiovasc Intervent Radiol* 2003 Dec;26(6):569–71.
22. Mallick A, Bodenham AR. Disorders of the lymph circulation: their relevance to anaesthesia and intensive care. *Br J Anaesth* 2003 Aug;91(2):265–72.
23. Boon JM, van Schoor AN, Abrahams PH, Meiring JH, Welch T, Shanahan D. Central venous catheterization -- an anatomical review of a clinical skill -- Part I: subclavian vein via the infraclavicular approach. *Clin Anat* 2007 Aug;20(6):602–11.
24. The clinical anatomy of several invasive procedures. American Association of Clinical Anatomists, Educational Affairs Committee. *Clin Anat* 1999;12(1):43–54.
25. Sulek CA, Blas ML, Lobato EB. A randomized study of left versus right internal jugular vein cannulation in adults. *J Clin Anesth* 2000 Mar;12(2):142–5.
26. Maggs PR, Schwaber JR. Fatal bilateral pneumothoraces complicating subclavian vein catheterization. *Chest* 1977 Apr;71(4):552–3.
27. Hamilton HC, Foxcroft DR. Central venous access sites for the prevention of venous thrombosis, stenosis and infection in patients requiring long-term intravenous therapy. *Cochrane Database Syst Rev* 2007;(3):CD004084.
28. Graham DR, Keldermans MM, Klemm LW, Semenza NJ, Shafer ML. Infectious complications among patients receiving home intravenous therapy with peripheral, central, or peripherally placed central venous catheters. *Am J Med* 1991 Sep 16;91(3B):95S–100S.
29. Chaiyakunapruk N, Veenstra DL, Lipsky BA, Saint S. Chlorhexidine compared with povidone-iodine solution for vascular catheter-site care: a meta-analysis. *Ann Intern Med* 2002 Jun 4;136(11):792–801.
30. Vallés J, Fernández I, Alcaraz D, Chacón E, Cazorla A, Canals M, et al. Prospective randomized trial of 3 antiseptic solutions for prevention of catheter colonization in an intensive care unit for adult patients. *Infect Control Hosp Epidemiol* 2008 Sep;29(9):847–53.
31. Hind D, Calvert N, McWilliams R, Davidson A, Paisley S, Beverley C, et al. Ultrasonic locating devices for central venous cannulation: meta-analysis. *BMJ* 2003 Aug 16;327(7411):361.
32. Brass P, Hellmich M, Kolodziej L, Schick G, Smith AF. Ultrasound guidance versus anatomical landmarks for subclavian or femoral vein catheterization. *Cochrane Database Syst Rev* 2015 Jan 9;1:CD011447.
33. Stone MB, Moon C, Sutijono D, Blaivas M. Needle tip visualization during ultrasound-guided vascular access: short-axis vs long-axis approach. *Am J Emerg Med* 2010 Mar;28(3):343–7.
34. Blaivas M, Brannam L, Fernandez E. Short-axis versus long-axis approaches for teaching ultrasound-guided vascular access on a new inanimate model. *Acad Emerg Med* 2003 Dec;10(12):1307–11.
35. Ball RD, Scouras NE, Orebaugh S, Wilde J, Sakai T. Randomized, Prospective, Observational Simulation Study Comparing Residents' Needle-Guided Vs Free-Hand Ultrasound Techniques for Central Venous Catheter Access. *Br J Anaesth* 2012 Jan 1;108(1):72–9.
36. Sommerkamp SK, Romaniuk VM, Witting MD, Ford DR, Allison MG, Euerle BD. A comparison of longitudinal and transverse approaches to ultrasound-guided axillary vein cannulation. *Am J Emerg Med* 2013;31(3):478–81.
37. Vogel JA, Haukoos JS, Erickson CL, et al. Is long-axis view superior to short-axis view in ultrasound-guided central venous catheterization? *Crit Care Med* 2015;43(4):832–9.
38. Shamir MY, Bruce LJ. Central venous catheter-induced cardiac tamponade: a preventable complication. *Anesth Analg* 2011 Jun;112(6):1280–2.
39. Gravenstein N, Blackshear RH. In vitro evaluation of relative perforating potential of central venous catheters: comparison of materials, selected models, number of lumens, and angles of incidence to simulated membrane. *J Clin Monit* 1991 Jan;7(1):1–6.

40. Dailey RH. Late vascular perforations by CVP catheter tips. *J Emerg Med* 1988 Apr;6(2):137-40.
41. Peres PW. Positioning central venous catheters--a prospective survey. *Anaesth Intensive Care* 1990 Nov;18(4):536-9.
42. Czepizak CA, O'Callaghan JM, Venus B. Evaluation of formulas for optimal positioning of central venous catheters. *Chest* 1995 Jun;107(6):1662-4.
43. Ryu H-G, Bahk J-H, Kim J-T, Lee J-H. Bedside prediction of the central venous catheter insertion depth. *Br J Anaesth* 2007 Feb;98(2):225-7.
44. Lee J-H, Bahk J-H, Ryu H-G, Jung C-W, Jeon Y. Comparison of the bedside central venous catheter placement techniques: landmark vs electrocardiogram guidance. *Br J Anaesth* 2009 May;102(5):662-6.
45. Golden LR. Incidence and management of large-bore introducer sheath puncture of the carotid artery. *J Cardiothorac Vasc Anesth* 1995 Aug;9(4):425-8.
46. Reuber M, Dunkley LA, Turton EPL, Bell MDD, Bamford JM. Stroke after internal jugular venous cannulation. *Acta Neurol Scand* 2002 Mar;105(3):235-9.
47. Oliver WC Jr, Nuttall GA, Beynen FM, Raimundo HS, Abenstein JP, Arnold JJ. The incidence of artery puncture with central venous cannulation using a modified technique for detection and prevention of arterial cannulation. *J Cardiothorac Vasc Anesth* 1997 Dec;11(7):851-5.
48. Domino KB, Bowdle TA, Posner KL, Spittellie PH, Lee LA, Cheney FW. Injuries and liability related to central vascular catheters: a closed claims analysis. *Anesthesiology* 2004 Jun;100(6):1411-8.
49. Ezaru CS, Mangione MP, Oravitz TM, Ibinson JW, Bjerke RJ. Eliminating Arterial Injury During Central Venous Catheterization Using Manometry. *Anesth Analg* 2009 Jul 1;109(1):130-4.
50. Toftegaard M, Rees SE, Andreassen S. Correlation between acid-base parameters measured in arterial blood and venous blood sampled peripherally, from vena cavae superior, and from the pulmonary artery. *Eur J Emerg Med* 2008 Apr;15(2):86-91.
51. Ho AM-H, Chung DC, Tay BA, Yu LM, Yeo P. Diluted Venous Blood Appears Arterial: Implications for Central Venous Cannulation. *Anesth Analg* 2000 Dec 1;91(6):1356-7.
52. Lim T, Ryu H-G, Jung C-W, Jeon Y, Bahk J-H. Effect of the bevel direction of puncture needle on success rate and complications during internal jugular vein catheterization. *Crit Care Med* 2012 Feb;40(2):491-4.
53. Lobato EB, Florete OG Jr, Paige GB, Morey TE. Cross-sectional area and intravascular pressure of the right internal jugular vein during anesthesia: effects of Trendelenburg position, positive intrathoracic pressure, and hepatic compression. *J Clin Anesth* 1998 Feb;10(1):1-5.
54. Clenaghan S, McLaughlin RE, Martyn C, McGovern S, Bowra J. Relationship Between Trendelenburg Tilt and Internal Jugular Vein Diameter. *Emerg Med J* 2005 Dec 1;22(12):867-8.
55. Beddy P, Geoghegan T, Ramesh N, Buckley O, O'Brien J, Colville J, et al. Valsalva and gravitational variability of the internal jugular vein and common femoral vein: ultrasound assessment. *Eur J Radiol* 2006 May;58(2):307-9.
56. Brederlau J, Greim C, Schwemmer U, Haunschmid B, Markus C, Roewer N. Ultrasound-guided cannulation of the internal jugular vein in critically ill patients positioned in 30 degrees dorsal elevation. *Eur J Anaesthesiol* 2004 Sep;21(9):684-7.
57. Sulek CA, Gravenstein N, Blackshear RH, Weiss L. Head Rotation During Internal Jugular Vein Cannulation and the Risk of Carotid Artery Puncture. *Anesth Analg* 1996 Jan 1;82(1):125-8.
58. Lieberman JA, Williams KA, Rosenberg AL. Optimal Head Rotation for Internal Jugular Vein Cannulation When Relying on External Landmarks. *Anesth Analg* 2004 Oct 1;99(4):982-8.
59. Wang R, Snoey ER, Clements RC, Hern HG, Price D. Effect of head rotation on vascular anatomy of the neck: an ultrasound study. *J Emerg Med* 2006 Oct;31(3):283-6.
60. Fortune JB, Feustel P. Effect of patient position on size and location of the subclavian vein for percutaneous puncture. *Arch Surg* 2003 Sep;138(9):996-1000; discussion 1001.
61. Boyd R, Saxe A, Phillips E. Effect of patient position upon success in placing central venous catheters. *Am J Surg* 1996 Oct;172(4):380-2.
62. He Y-Z, Zhong M, Wu W, Song J-Q, Zhu D-M. A comparison of longitudinal and transverse approaches to ultrasound-guided axillary vein cannulation by experienced operators. *J Thorac Dis* 2017;9(4):1133-9.
63. Maddali MM, Arora NR, Chatterjee N. Ultrasound Guided Out-of-Plane Versus In-Plane Transpectoral Left Axillary Vein Cannulation. *J Cardiothorac Vasc Anesth* 2017;31(5):1707-12.